


LECTURE NOTES

For Health Science Students

Physical Diagnosis



Editors

Gashaw Messele
Mensur Osman
Zeki Abdurahman

University of Gondar

In collaboration with the Ethiopia Public Health Training Initiative, The Carter Center,
the Ethiopia Ministry of Health, and the Ethiopia Ministry of Education

2005



Funded under USAID Cooperative Agreement No. 663-A-00-00-0358-00.

Produced in collaboration with the Ethiopia Public Health Training Initiative, The Carter Center, the Ethiopia Ministry of Health, and the Ethiopia Ministry of Education.

Important Guidelines for Printing and Photocopying

Limited permission is granted free of charge to print or photocopy all pages of this publication for educational, not-for-profit use by health care workers, students or faculty. All copies must retain all author credits and copyright notices included in the original document. Under no circumstances is it permissible to sell or distribute on a commercial basis, or to claim authorship of, copies of material reproduced from this publication.

©2005 by Gashaw Messele, Mensur Osman, Zeki Abdurahman, Getachew Tizazu, Yoseph Mamo, Fekadu Zeleke, Nejmudhin Reshad, and Andinet Worku

All rights reserved. Except as expressly provided above, no part of this publication may be reproduced or transmitted in any form or by any means, electronic or mechanical, including photocopying, recording, or by any information system, without written permission of the authors.

ACKNOWLEDGMENTS

The authors greatly acknowledge and appreciate the EPHTI, Carter Center, for its initiative to prepare this teaching material and all the financial, technical and moral support.

We would also like to extend our gratefulness to our students, patients and all hospital and faculty staff with out which the relevant formations in this material would have not been made available.

This material has passed through evaluation at internal and ex e

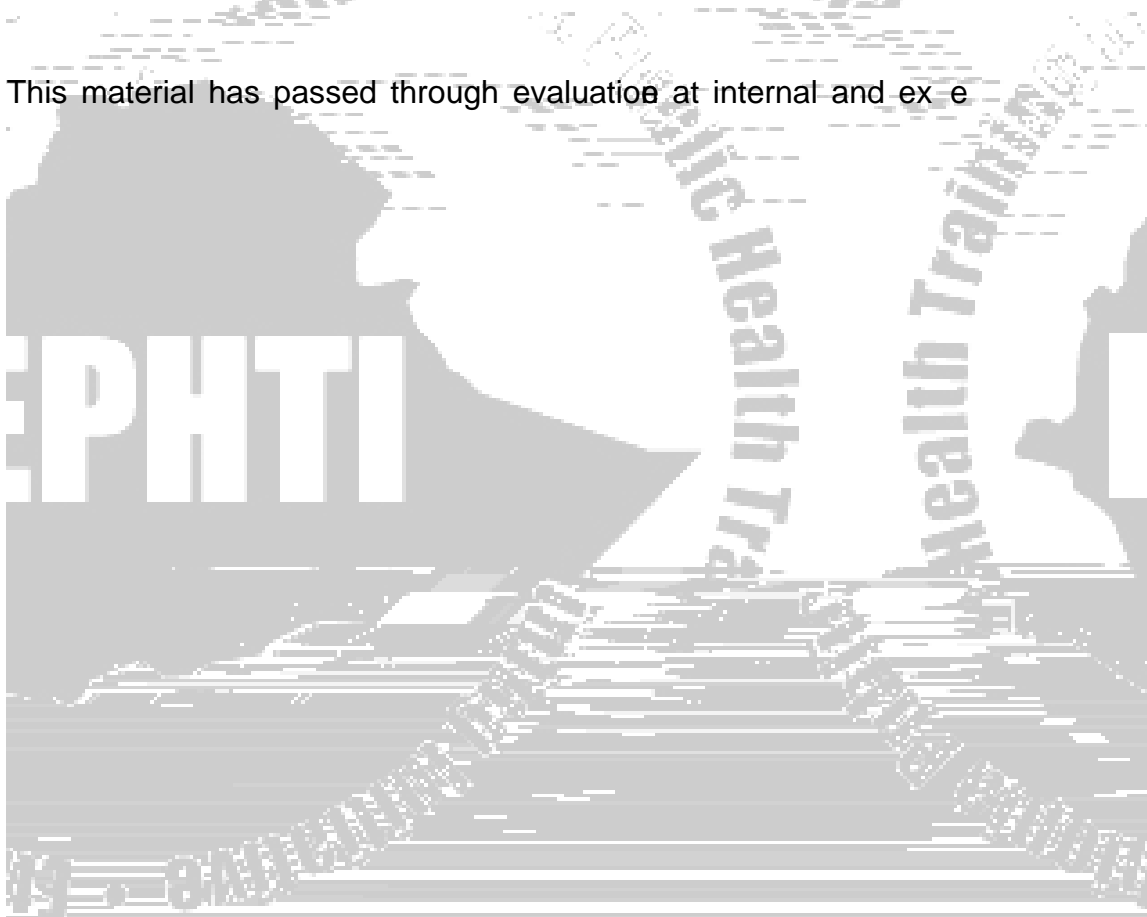


TABLE OF CONTENTS

	Title	Page
CHAPTER ONE	Introduction to Clinical Medicine	1
CHAPTER TWO	Clinical History and Physical Examination	6
CHAPTER THREE	Approach to the Respiratory System	19
CHAPTER FOUR	Approach to Cardiovascular Examination	34
CHAPTER FIVE	Approach to the Gastrointestinal System (GIS) And Genitourinary system	53
CHAPTER SIX	Approach to Glands	78
CHAPTER SEVEN	Approach to Musculoskeletal System	92
CHAPTER EIGHT	Approach to the Integumentary System	112
CHAPTER NINE	Approach to Special Examinations	122
CHAPTER TEN	Approach to Examination of the Nervous System	138

also from their trainers as a technique of teaching through challenge. This Socratic approach, question based learning is time honored and very much alive in medicine to this day.

Clinical reasoning based on facts (symptoms and signs) in the history and examination has to be tested against basic science background knowledge acquired earlier. Clinical diagnosis requires both aspects of logic which are analysis and synthesis. First, the process of breaking up each problem then trying to fit these again into one particular syndrome. A syndrome usually doesn't identify the precise cause of an illness, but it narrows the possibilities and may suggest certain special clinical and laboratory studies.

Laboratory results must be seen as supporting evidence and should not be allowed to dictate over a meticulous clinical evaluation. This is because the reliability of laboratory data depends on the equipment and the performer's ability. A careful communication, observation and study of the patient can not be replaced by laboratory studies. A wise clinician should be purposeful in ordering a test. Ordering the whole battery of tests to get to a diagnosis is as unprofessional as a policeman who indiscriminately imprisons all the suspects of a crime. Such practice is more harmful than beneficial because it leads to more confusion during interpretation. It will also lead to inefficiency of the laboratory team due to unnecessary overload of work.

Caring for patients is an indispensable trait of a physician who should have an interest in all, be it poor or rich, be it humble or proud. A physician should respect the patient by being nonjudgmental of the lifestyle, attitude and values different from that of him/her self. Without a deep knowledge of the patient's social and environmental characteristics, it is difficult to gain rapport with the patient or insight into the illness. Some patients are overly worried while others have neglected a serious problem; others still pretend disease to get attention or as an attempt to remove them selves from stressful situation.

Patient care begins with the development of a personal relationship between the patient and physician. In the absence of trust and confidence on the part of the patient, the effectiveness of most therapies fails. A physician should have integrity by making himself

Physical Diagnosis

available for help, expression of sincere concern, taking time to explain the aspects of illness to the patient. How much a patient is told should depend on the individual ability and capacity to deal with the possibility of imminent death. Gradual and not abrupt disclosure of bad news is the best strategy.

The best way to acquire these different skills is by repeatedly practicing them. Practice enables good habits to develop. Systematic habits of interviewing, examining and thinking (analysis and synthesis) makes clinical practice not only a good method of problem solving, but also a fulfilling and joyous professional life. Therefore, the basis of the clinical and diagnostic



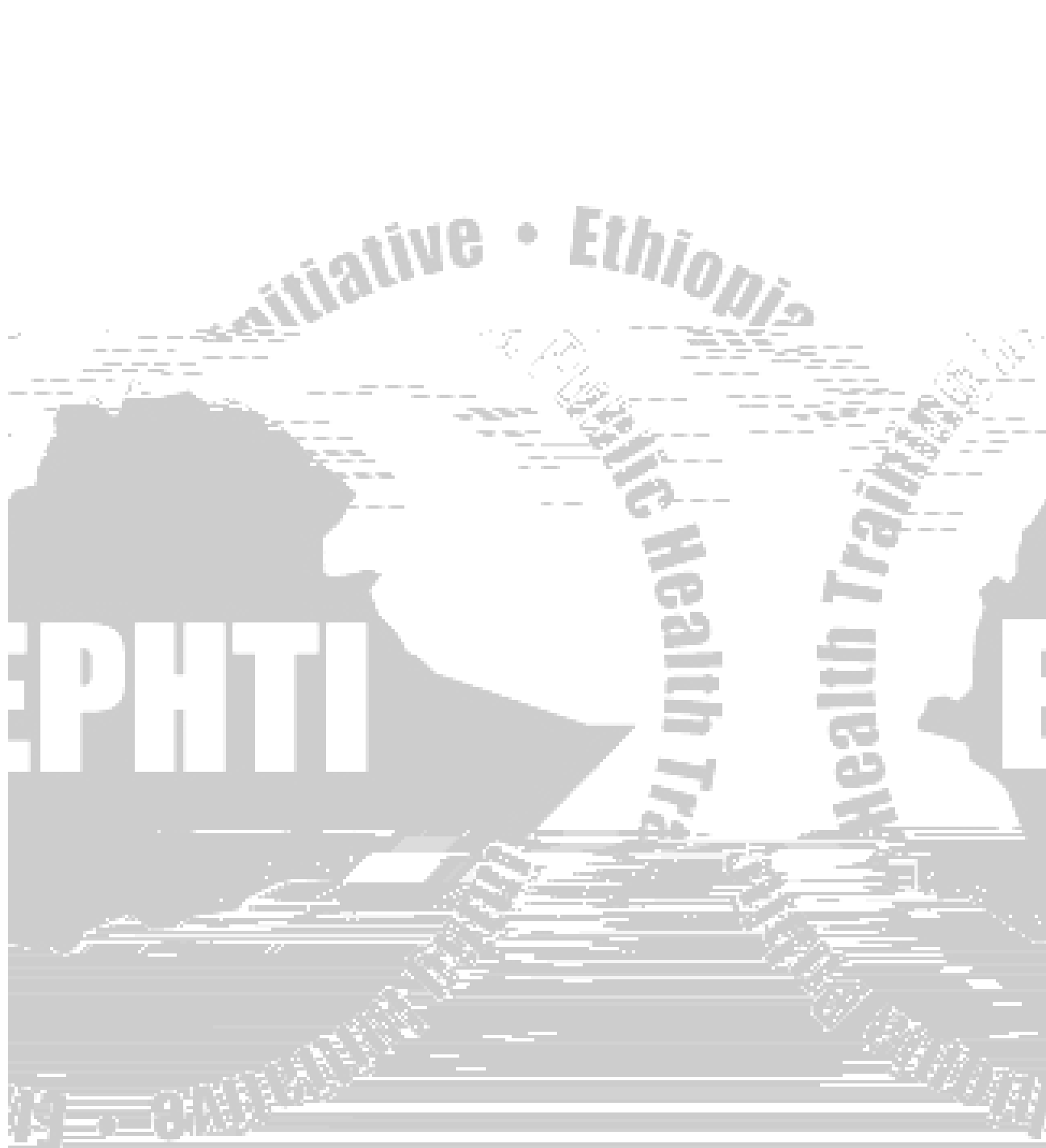
wrong. The duty of the physician is simply put as “to do the right thing not necessarily the good one”, because the good thing may not always be right thing to do. The right thing is done only when he knows the basic ethical issues concerning clinical practice. Without this knowledge the physician will be relying only on his past experience, which may not always be reliable.

Patient's autonomy involves the liberty to refuse recommended intervention and choosing among the available alternatives. Informing the patient adequately to be able to make decision to accept or refuse an intervention before acquiring his consent or permission is a physician's duty. In a situation where the patient is not able to make such decision due to emergency, clouded consciousness or other situations, the physician should act in the best interest of the patient and to the best of his/her capacity avoiding harm and weighing very carefully that the advantage of the intervention is greater than the danger to the life of the patient. The clinician should always pass responsibility to a better-qualified person when this is available. When family members are available they can act as surrogates, all the same- the physician should be convinced that the patient's best interest is safeguarded.

Conflict between patient's autonomy and 'his best interest' can arise when the patient refuses an intervention that can save his life. Here, the duty of physician is to have patience to educate and persuade the patient for a better decision. Withholding intervention like cardiopulmonary resuscitation in a patient with multiple organ failure from chronic illness could be justified while in an accident or acute illness it should be done. Administering high dose of narcotics to a terminally ill patient without pain or an indication is unethical as it can be considered as an attempt to hasten death by respiratory suppression (Euthanasia). But the same act in a patient with severe pain of terminal illness is ethical as the primary effort in this case is to control pain, to give patient comfort and dignity.

Conflict of patient and physicians' interest arises in the following situations; when physicians are given gifts for or to prescribe drugs of a certain company, or when physicians order unnecessary laboratory investigation which costs patient but is of gain to the physician. Covering-up for the mistakes done by oneself or that of a colleague is as





Initiative • Ethiopia

Public Health Training

Public Health Training

EPHTI

2019 • 8th Edition



Initiative • Ethiopia

Public Health Training

Public Health Training

EPHTI

2019 • 8th Edition

Physical Diagnosis

A patient goes to a health institution, perhaps for the first time in his life, on the other hand with apprehension and suspicion and with the intention of unfolding his life story to the health professional that he regards as his best confidant and whom he expects to respect his human dignity. Patients often want to talk and explain their problem and, by doing so, get some peace of mind. It should also be remembered that the patient is a person not simply a case.

Avoid careless remarks that may hurt the feelings of your patient and thereby jeopardize the friendly communication you would like to establish between your patient and yourself. Besides, remember that any emotional upset may change the course of the illness of the patient. So, you should try to alleviate anxieties by repeated reassurance.


It is also important to note that the medical and paramedical personnel should respect the professional secrecy so much expected of them. Thus, a medical record is strictly the property of the medical staff looking after the patient and should not be exposed to any one outside the staff, nor should the contents be told to others at any time.

Therefore, history taking demands:

Socio-Demographic Data

Certain socio-demographic data in the health history typically precede the account of the patient's history. These are:

1. The date and the time



Clinical History

The clinical history



Here, try to find out if other signs and symptoms have developed with the chief complaints.

- **Character and Location:** If we take pain as an example, it is important to ask whether the pain is:

Stabbing

Burning

Pricking

Aching

The distinction between a colic which waxes and wanes and may cause a patient to roll about and a steady pain like that of peritonitis which causes the patient try to avoid all movements may be very important. Furthermore, the location of the pain should be precise. One should try to find out if the pain radiates to other areas and describe the extent and manner of radiation.

- **Exacerbating and Remitting Factors:** This part of the history is concerned with what brings on and what makes the problem worse. For example, a chest pain, which always comes on after a certain amount of exertion or made worse by exertion is almost certainly due to ischemia of the heart (angina). There can also be relieving factors for pains. For example, rest usually promptly relieves upper gastro intestinal pains, like duodenal ulcers.
- **Effect of treatment:** Patients might have taken drugs prior to their presentation to the health institution. It is very important to ask about the effect of such drugs on the illness.
- **Negative- Positive statements:** These inquiries are conducted as thoroughly as possible with a view to constructing a differential diagnosis.

A negative statement may be as important as a positive statement. These statements are expressed in terms of signs and symptoms but not diseases. For example, in a patient presenting with hemoptysis, statements like “ he denies night sweats, chronic cough, he has not lost weight, he doesn’t have loss of appetite” are as important as “ he suddenly developed fever, chills, rigors, chest pain aggravated by deep breathing, and cough productive of blood streaked sputum two days ago.” The negative statement tries to rule out pulmonary tuberculosis, while the positive statement implies the diagnosis of pneumonia.

- **The mode of arrival:** The last paragraph of the history of the present illness should state how the patient came to the health institution i.e., on a stretcher or walking. Also there should be mention of any color, strength, or weigh change. These factors will give some knowledge of the general condition of the patient.

4. Past illness: This includes important illnesses from infancy onwards. It comprises:

Childhood illnesses like measles, rubella, mumps, w



General: This includes history of recent weight change, weakness, fatigue, fever, etc.

H.E.E.N.T. (Head, Eye, Ear, Nose, Mouth and Throat)

Head: Headache or injuries.

Eyes: double vision, blurring, photophobia, itching, pain, redness, excessive tearing, etc.

Ear: hearing problem, tinnitus, vertigo, earaches, discharge, etc.

Nose: frequent colds, nasal stuffiness, nasal discharge or itching; nasal bleeding, etc.

Mouth and Throat: sore tongue, frequent sore throat, and hoarseness of voice, dry mouth, oral thrush, dental carries, etc.

Neck: pain, stiffness, swollen glands, "lumps", etc

Lympho-glandular system: This includes enlarged glands, lumps in the breasts, and discharge from the nipples, goiter with or without heat or cold intolerance. descent of testis.

Respiratory system: This includes inquiry about history of

- Cough
- Production of sputum (including the odor, color and amount)
- Hemoptysis
- Difficulty of breathing
- Wheezing
- Asthma
- Pulmonary tuberculosis
- Chest pain

Cardiovascular system: This includes inquiry about history of:

- Dyspnea (including degree of exercise tolerance)
- Palpitation
- Orthopnea (number of pillows required), paroxysmal nocturnal dyspnea
- Cough (dry or productive)

- Hemoptysis
- Chest pain (With character, location and radiation)
- Syncope
- Hypertension
- Swelling of the feet

Gastro intestinal system: This includes inquiry about history of Difficulty of swallowing, heartburn, nausea, vomiting, abdominal pain, constipation, diarrhea, food intolerance, excessive



Integumentary system (Skin, Hair and Nails): History of dry or moist skin, rashes, ulcers, urticaria, hair distribution and pigmentary changes, changes in color and shape of the fingernails.

Musculo- skeletal system: History of bony deformities, joint pain and /or swelling, limping, loss of function of limbs or joints, leg swelling.

Central nervous system: History of fainting, seizures, weakness, paralysis, numbness or loss of sensation, tingling sensation, tremor or other involuntary movements, insomnia, poor memory, headache, disturbance of speech, disturbance of sphincter control, delusion, hallucination, illusion, etc.

6. Personal – Social history: In order to have a complete picture of the patient as a person and to interpret his/her disease in the light of his social back ground, the personal and social history is very important .It is recorded as follows;

- **Early development:** place of birth and where the patient lived before, childhood development, health and activities.
- **Education:** School history, achievements, and failures,
- **Marital status:** whether the patient is married or not, history of extramarital sexual activity, or sexual promiscuity.
- **Work Record:** type of work and age begun, the income, number of jobs, success or failure regarding shift of jobs, occupational hazards, and attitudes to work, employers and work mates.
- **Home surroundings:** their sanitary condition, and the possible existence of over crowding or of loneliness, what pets are kept? etc.
- **Habits:** dietary history; history of substances like alcohol, tobacco, chat, etc. One has to try to quantify the daily alcohol and tobacco consumption.
- **Others:** ethnic origin, religion, beliefs, etc.

7. Family history: The family history of the patient is very important because it provides information about the health status of immediate relatives, hereditary illnesses, and the emotional difficulties which may be the cause of symptoms or maladjustments of the patient. It is recorded as follows:

- **Siblings:** list their ages and current health status (If dead, mention the date and possible cause of death)
- **Father and Mother:** list their ages and current health status (If dead, the date and possible cause of death should be mentioned)
- **Familial Diseases:** diseases like tuberculosis, asthma, diabetes mellitus, hypertensive disorders, migraine, etc should be asked.

Overview of Physical examination

It is always advisable to follow the points below while examining the patient:

Examination should take place with good lighting and in a quiet environment.

It is advisable to examine a supine patient from the patient's right side

By words or gestures, be as clear as possible in your instructions.

If possible try to demonstrate the patient what to do rather than giving verbal instructions alone.

Keep the patient informed as you proceed with your examination.

While examining the patient, it is helpful to move "from head to toe."

The basic steps of physical examination are:

Inspection

Palpation

Percussion

Auscultation

The components of comprehensive examination are:

General appearance: Is the patient acutely sick, chronically sick looking or not sick looking at all? Is the patient in cardio respiratory distress or not?

Vital signs:

- Pulse (rate, volume, character, radio femoral delay)
- Blood pressure (specify arm and the position it was taken)
- Respiratory rate
- Temperature (Specify the location it was taken)

H.E.E.N.T (head, eye, ear, nose, mouth and throat)

Lymph glandular system

Respiratory system

Cardiovascular system

Gastro intestinal system

Genito urinary system

Integumentary system


Mesculo skeletal system

Central nervous system.

Examination of each system will be discussed separately.

Review Questions

1. What are the contents of a clinical history?
2. What are the components of HPI?
2. What are the basic steps of physical examination?
3. What are the components of the personal social history?



CHAPTER THREE

APPROACH TO THE RESPIRATORY SYSTEM

Objectives

By the end of this chapter, the student should be able to

1. Explain the common respiratory symptoms and their significance.
2. Explain the important steps of examination of the respiratory system.
3. Demonstrate the basic techniques of examination of the respiratory system and
4. Explain the significance of the important physical findings in the respiratory system.

Introduction

The respiratory system consists of the lungs, the branching airways, the gaseous exchange membranes, the rib cages, and the respiratory muscles.

Diseases of the respiratory system are one of the commonest causes of mortality and morbidity throughout the world. As with every aspect of diagnosis in medicine, thorough examination of the system is very important to properly diagnose any respiratory problem.

Respiratory symptoms

Cough: It is the commonest symptom of diseases of the lungs and air passages. A person may cough voluntarily, but more typically cough is a reflex response to stimuli that irritate receptors in the larynx, trachea, or large bronchi. The stimuli include both external agents such as irritating dusts, foreign bodies, and even extremely hot or cold air, and internal substances such as mucus, pus, and blood. Inflammation of the respiratory mucosa, and pressure or tension on the air passages as from a tumor or enlarged peribronchial lymph node may also cause coughing.

The following are types of questions we need to ask to determine the timing of cough:

Is it a new symptom or more chronic?

How frequent is it?

When does it occur?

Is it seasonal?

Are there factors that seem to precipitate or aggravate it?

Assess the quality of cough by asking whether it is dry or productive of sputum. If the cough is productive, try to describe the color, paroxysms, odor and volume of sputum. The amount of sputum produced in 24 hours can be quantified using teaspoon or coffee cup.

It is also important to understand that mucoid sputum is translucent, white, or gray; purulent sputum is yellowish or greenish; while muco purulent sputum has both components. Large volume of purulent sputum suggests bronchiectasis or lung abscess.

Hemoptysis: It is the expectoration

The clinician should ask if the patient has ever experienced hemoptysis and assess the volume of blood produced together with other attributes of the sputum. It is also good to focus on the setting in which the hemoptysis occurred and on other associated symptoms.

Dyspnea: This is a non-painful but uncomfortable awareness of breathing that is inappropriate to the circumstances. Only the patient can report the dyspnea. Dyspnea commonly results from cardiac or bronco-pulmonary problems.

Dyspnea should be characterized as to whether it occurs at rest or only after certain type of exertion and whether it is persistent or intermittent. It is also important to record some measures of exercise tolerance such as the distance walked before the patient has to stop and rest.

Chest Pain: Chest pain, which is defined as pain or discomfort in the chest, can arise from any one of the following thoracic structures:

- The heart
- The aorta
- The trachea and large bronchi
- The esophagus
- The chest wall
- The parietal pleura

Chest pains associated with pulmonary diseases usually arise from the pleura. Pleuritic chest pain is sharp and stabbing, and is aggravated by deep breathing or coughing. It occurs when the underlying pleura is inflamed, most commonly by infection in the underlying lung. Pain caused by spontaneous pneumothorax may have more of an aching character than the stabbing pain of pleurisy.

The Respiratory system

Locating Findings on the chest


To describe an abnormality on the chest, you need to locate it in two dimensions: along the vertical axis and around the circumference of the chest.

To locate vertically, you must be able to number the ribs and interspaces accurately. The



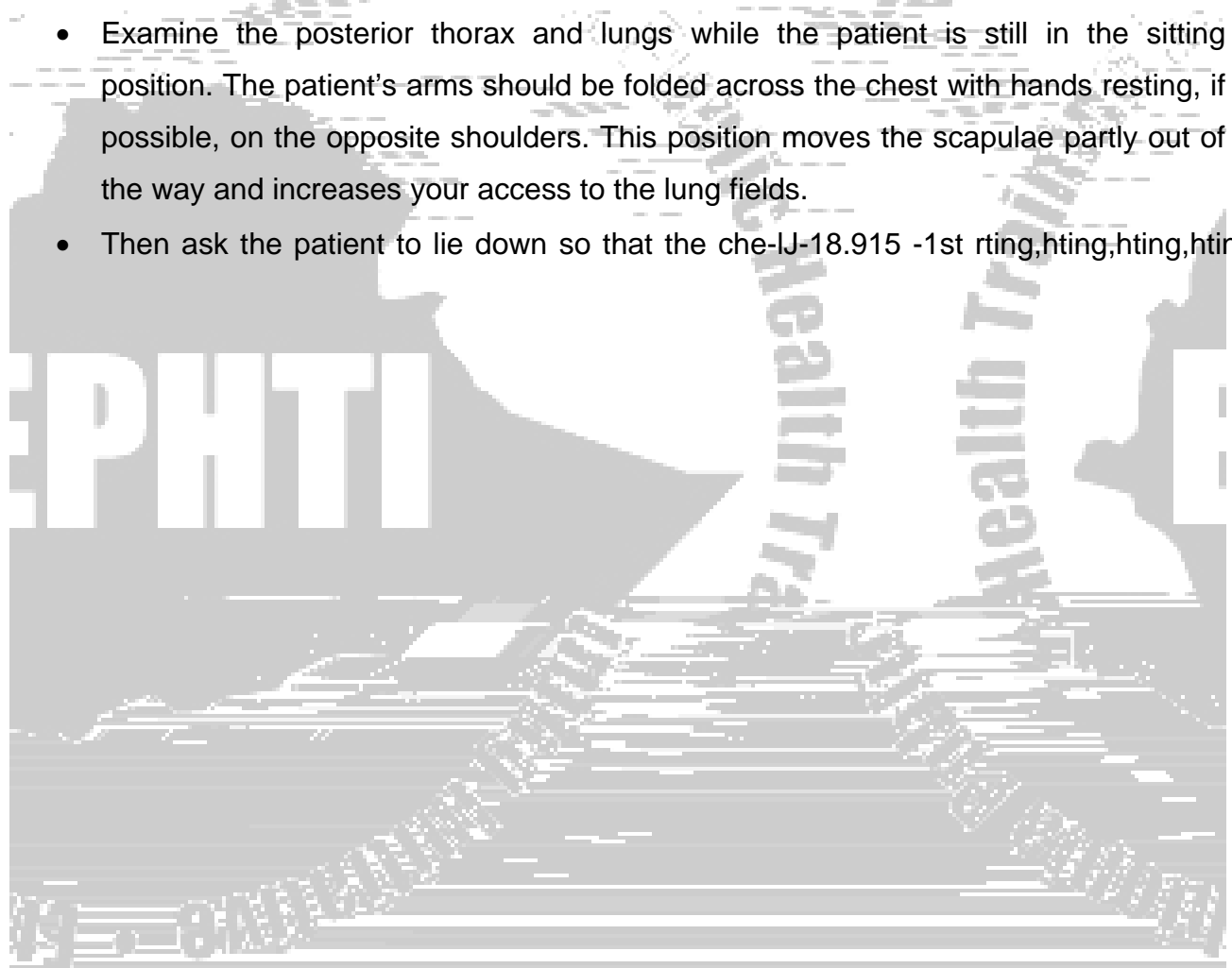


To locate findings around the circumference of the chest a series of vertical lines are used.



General approach

- Arrange the patient's gown so that you can see the chest fully, but cover a woman's anterior chest while you are examining the back. Ideally the patient should be comfortably resting on a bed sitting at angle of 45° and supported by pillows.
- Proceed in an orderly fashion: inspect, palpate, percuss, and auscultate. Compare one side of the chest with the other. With this side-to side comparison, a patient serves as his or her own control.
- Examine the posterior thorax and lungs while the patient is still in the sitting position. The patient's arms should be folded across the chest with hands resting, if possible, on the opposite shoulders. This position moves the scapulae partly out of the way and increases your access to the lung fields.
- Then ask the patient to lie down so that the che-IJ-18.915 -1st rting,hting,hting,hting,6abfho4

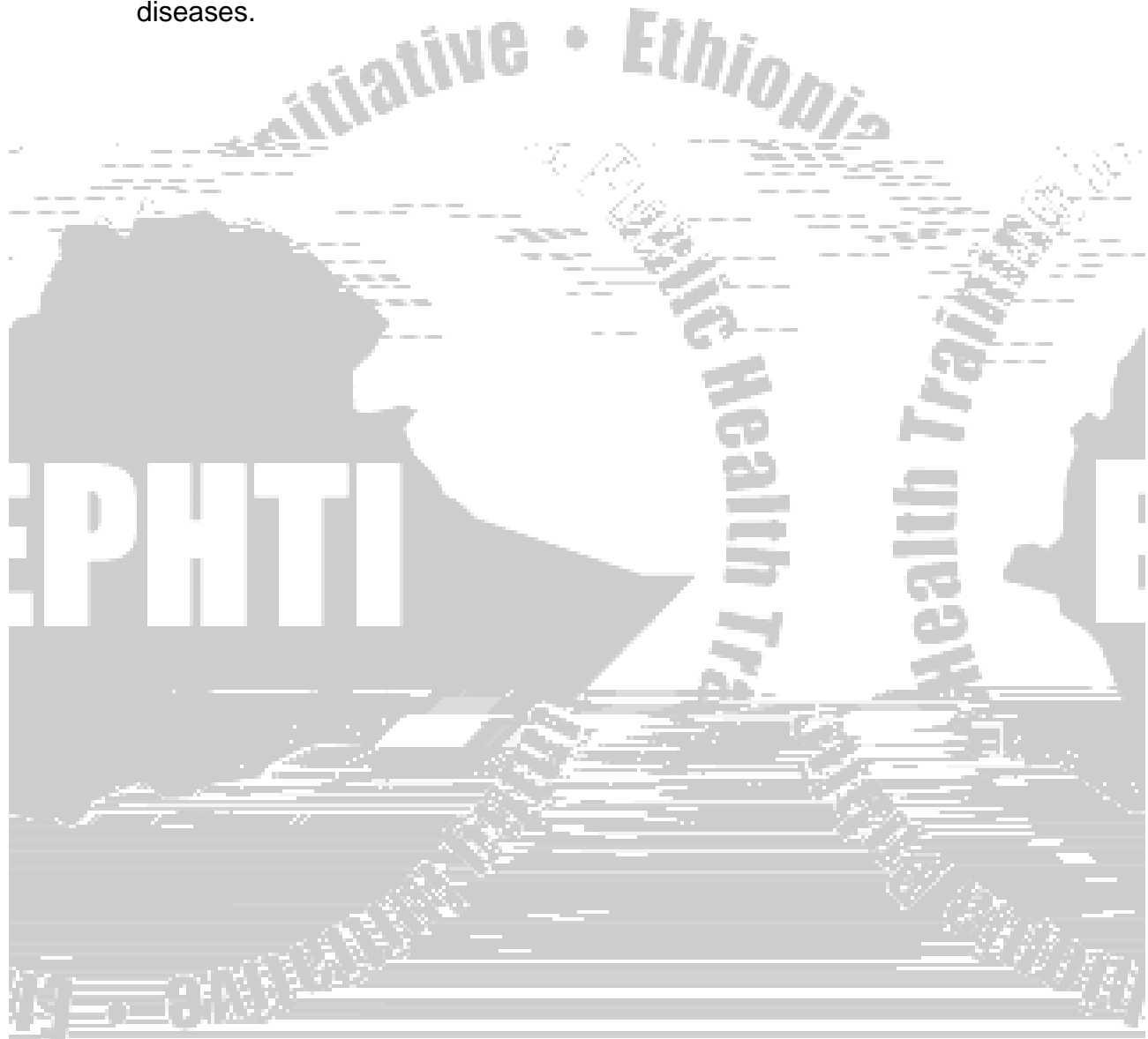


Inspection: this part of physical examination includes:

-



- **Gibbus:** a posterior angular or wedge shaped deformity of the spine. It is caused by fracture or spinal tuberculosis (Pott's disease).
- **Flattening of the chest:** Example: Pulmonary fibrosis
- **Barrel-shaped chest:**
- **Pigeon chest:** This is seen in bronchial asthma and chronic obstructive lung diseases.



By using measuring tapes: Chest expansion can easily be recorded with a tape measure around the chest at the level of the nipple. In a fit young man the chest may expand 5-8 cm, and in patients with severe airway obstructive diseases it may expand less than 1cm.

Assessment of tactile fremitus: Ask the patient to repeat the word 'ninety-nine' or the Amharic word "Arba-Arat" and compare both sides of the chest symmetrically. If fremitus is faint, ask the patient to speak more loudly or in a deep voice. Fremitus is decreased or absent:

- When the voice is soft
- When transmission of vibrations from the larynx to the surface of the chest is impeded.

The cause can be an obstructed bronchus, pleural effusion, pulmonary fibrosis, pneumothorax or very thick chest wall.

Fremitus is increased when the transmission of sound is increased, as through the consolidated lung of lobar pneumonia.

Percussion

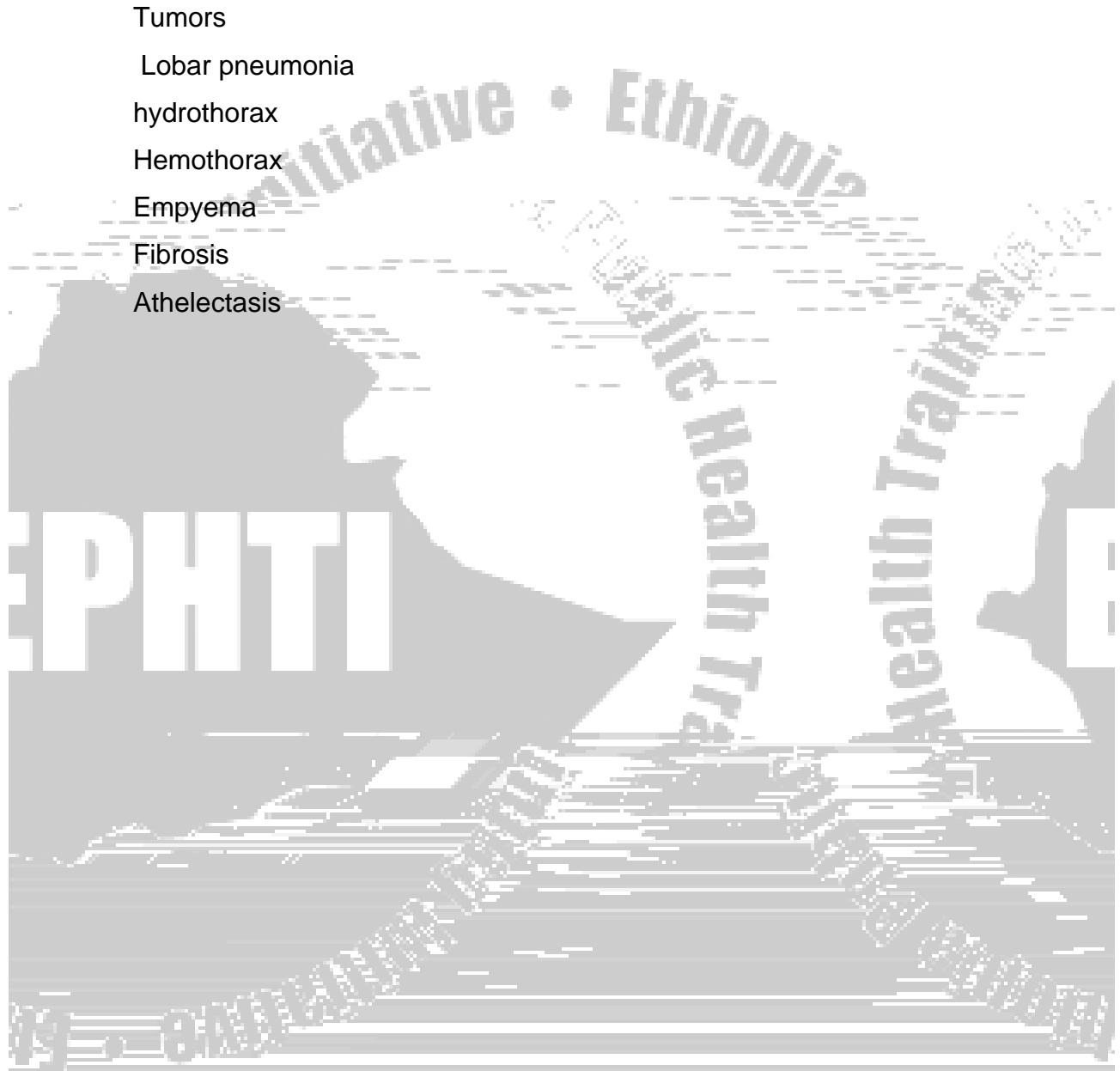
Percussion is a useful technique and without an X-ray can be used to distinguish reliably between the presence of pneumothorax and pleural effusion when the physical signs may be otherwise identical. It helps to determine whether the underlying tissues are air filled, fluid filled or solid.

One should systematically compare the percussion note on two equivalent sides of the chest. It is usually sufficient to percuss three or four areas anteriorly, three or four areas on the back, and two in the axillae. The findings on both sides of the chest should be compared symmetrically.

Physical Diagnosis

In a healthy individual, a resonant noise is produced upon percussion of the chest. Resonant sound is of low pitch and clear in character. Causes of dullness to percussion are:

- Tumors
- Lobar pneumonia
- hydrothorax
- Hemothorax
- Empyema
- Fibrosis
- Athelectasis



The quality of breath sounds have been classified in to three categories:

Vesicular: these are soft and low pitched sounds. They are heard through out inspiration, continue without pause in to expiration, and then fade away about one third of the way through expiration. Vesicular breath sounds are the normal breath sounds.

Vesicular breath sounds probably originate in the larger airways and when heard through normal lungs, the attenuating and filtering effect of the alveoli produces rather quiet low pitched rustling sounds

Bronchial: these are louder and higher in pitch. There is a short silent period between the inspiratory and expiratory sounds, and the expiratory sound lasts longer than the inspiratory one. Classically they are heard over an area of consolidated lung in cases of pneumonia.


Bronchovesicular: these are intermediate. Inspiratory and expiratory sounds are about equal in length, and a silent period between them may or may not be present. These are often heard in the first and second interspaces anteriorly and between the scapulae. Bronchial breath sounds probably originate from the same larger airways but when the lung between these airways and chest wall is airless as a result of consolidation, collapse, or fibrosis, the breath sounds are heard with relatively little loss by filtration and attenuation. The sound resembles that obtained by listening over the trachea, although the noise there is louder

Added sounds

Added sounds may arise in the lung or in the pleura. Sounds resembling pleural friction rubs may be produced by movements of the stethoscope on the patient's skin or of the examiner's hands or cloths against a stethoscope.

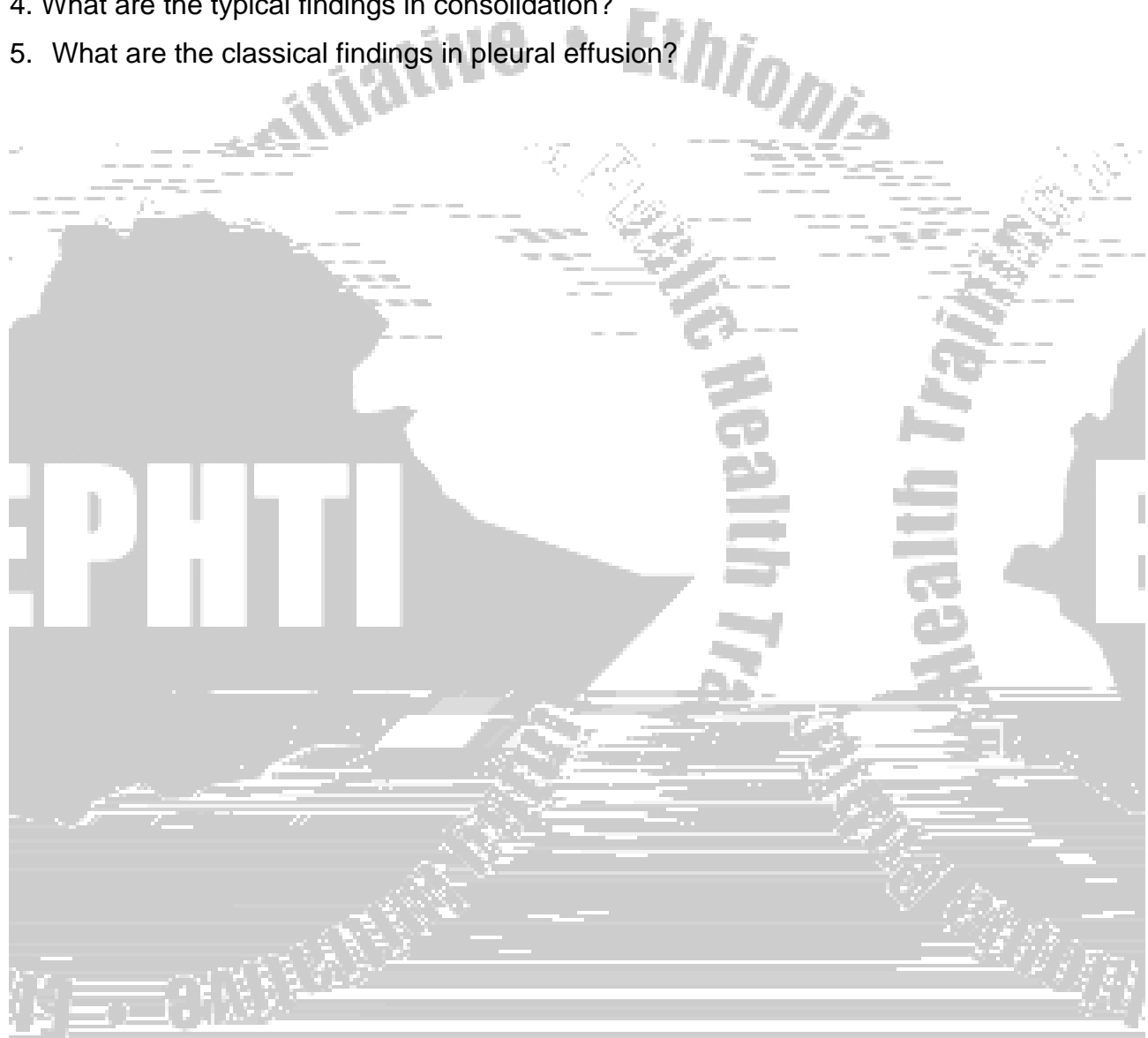
- Pleural friction rub is characteristic of pleural inflammation and occurs at a stage when there is pain. It has a rubbing character.

- Wheezes are musical sounds associated with air way narrowing. The noise is often inspiratory and expiratory and it is fairly obvious that it originates from the upper airways.
- Crackles are short, explosive sounds often described as bubbling. It is more likely that they are produced by sudden changes in gas pressure related to the sudden opening of previously closed small airways. Crackles may be due to abnormalities of the lungs (pneumonia, early congestive he



Review Questions

1. Discuss the common respiratory symptoms including their significance.
2. Enumerate the disease conditions, which can give dullness to percussion.
3. Describe the different types of breath sounds including their significance.
4. What are the typical findings in consolidation?
5. What are the classical findings in pleural effusion?

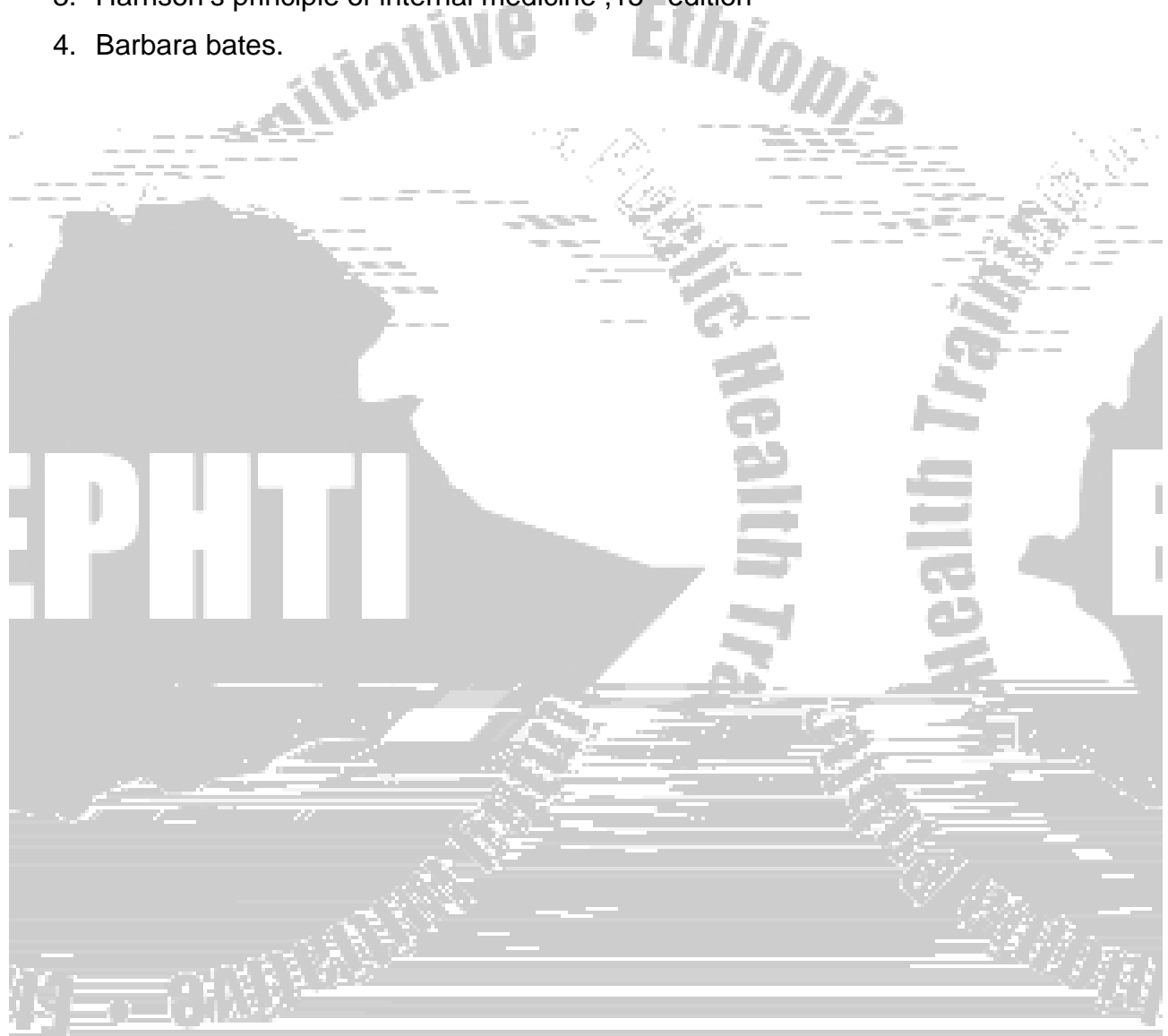


Glossary

1. **Orthopnea:** is a dyspnea that occurs when the patient is lying down but improves upon sitting up. It is classically quantified according to the number of pillows on which the patient sleeps.
2. **Paroxysmal nocturnal dyspnea:** describes episodes of sudden dyspnea and orthopnea that awakens a patient from sleep, usually 1 to 2 hours after going to bed.
3. **Wheezes:** are musical respiratory sounds that may be audible both to the patient and to others.
4. **Edema:** refers to the accumulation of excessive fluid in the interstitial spaces which appears as swelling.
5. **Hemoptysis:** is the coughing or “spitting up” of blood, which may vary from blood-streaked sputum to pure blood.
6. **Cough:** is an explosive expiration that provides a protective mechanism for clearing the tracheobronchial tree of secretions and foreign materials.
7. **Stridor:** is a chiefly inspiratory wheeze, which suggests airway obstruction in the larynx or trachea.
8. **Sinus:** blind, inflammatory, tube-like structure opening onto the skin
9. **Fremitus:** palpable vibrations transmitted through the bronchopulmonary tree to the chest wall when the patient speaks.
10. **Pleural effusion:** fluid in the pleural cavity
11. **Pneumothorax:** air in the pleural cavity
- 12.


BIBLIOGRAPHY

1. Edemariam Tsega: A guide to writing medical case reports, Research and publication office, A.A.U, 1985.
2. Michael S: Hutchison's clinical methods, 9th ed, 1989.
3. Harrison's principle of internal medicine ,15th edition
4. Barbara bates.



CHAPTER FOUR

APPROACH TO CARDIO



Tab. 4.1 New York Heart Association Functional Classification

Class I: No limitation of physical activity
No symptoms with ordinary exertion

Class II: Slight limitation of physical activity
Ordinary activity causes symptoms

Class III: Marked limitation of physical activity

CC



Symptoms of Peripheral Vascular Disease

Symptoms of Arterial occlusion:

Acute: pain, loss of function, altered cutaneous sensation, gangrene

Chronic: Intermittent claudication (pain around calf muscle on walking) which gets relieved with rest

Symptoms of Venous insufficiency:

- Swelling and pain of the affected limb

Physical Examination

Equipment Needed

- Stethoscope
- A Blood Pressure apparatus
- A Moveable Light Source or pen light

General Considerations

- The patient must be properly undressed above the waist.
- The examination room must be quiet to perform adequate auscultation.
- Observe the patient for general signs of cardiovascular disease
 - Breathing pattern
 - Cyanosis,
 - Finger clubbing,
 - Edema

General examination related to CVS examination

Observation

HEENT

Face

- Malar flush (thin face, purple cheeks) may be found in mitral stenosis.
- Lips for (cyanosis).

Eyes

- Xanthelasma or corneal arcus indicates hyperlipidemia
- Pallor of the conjunctiva indicates anemia
- Icterus may be found in acutely congested liver
- Exophthalmus may be seen in thyrotoxicosis.

Hands

- *Clubbing* of fingers may be seen :
 - Cyanotic congenital heart disease
 - Infective endocarditis
- *Peripheral cyanosis and Perfusion*
- *Splinter hemorrhages* :- vertical linear hemorrhages beneath the nails
- *Osler's nodes* :- Tender lumps in pulp of fingertips which may be found in endocarditis
- *Janeway lesions*:- are painless red macules on the wrist and palm which may be seen in patients with acute infective endocarditis
- *Nicotine stains*: - indicate chronic smoking which is a major risk factor for atherosclerosis.

Arterial Pulses

Components of arterial examination include

- Rate
- Rhythm
- Character
- Volume (amplitude)
- Radio-femoral delay

Major Arteries: Major arteries Radial, Brachial, Carotid, Femoral, Popliteal, Posterior Tibial, Dorsalis pedis. All arteries should be palpated symmetrically at the same time except carotid arteries, as this could cut off the blood supply to the brain and cause syncope.

Rate and Rhythm: The radial artery is preferred

1. Compress the radial artery with your index and middle fingers
2. Note whether the pulse is regular or irregular.
3. Count the pulse for one full minute.
4. Record the rate and rhythm.

Pulse classification in adults

1. Based on the rate

Normal: 60 - 100 beats / min

Bradycardia: < 60 beats / min

Tachycardia: > 100 beats / min

2. Based on rhythm

Regular

Regularly irregular, e.g. ectopic beats, 2nd degree heart block

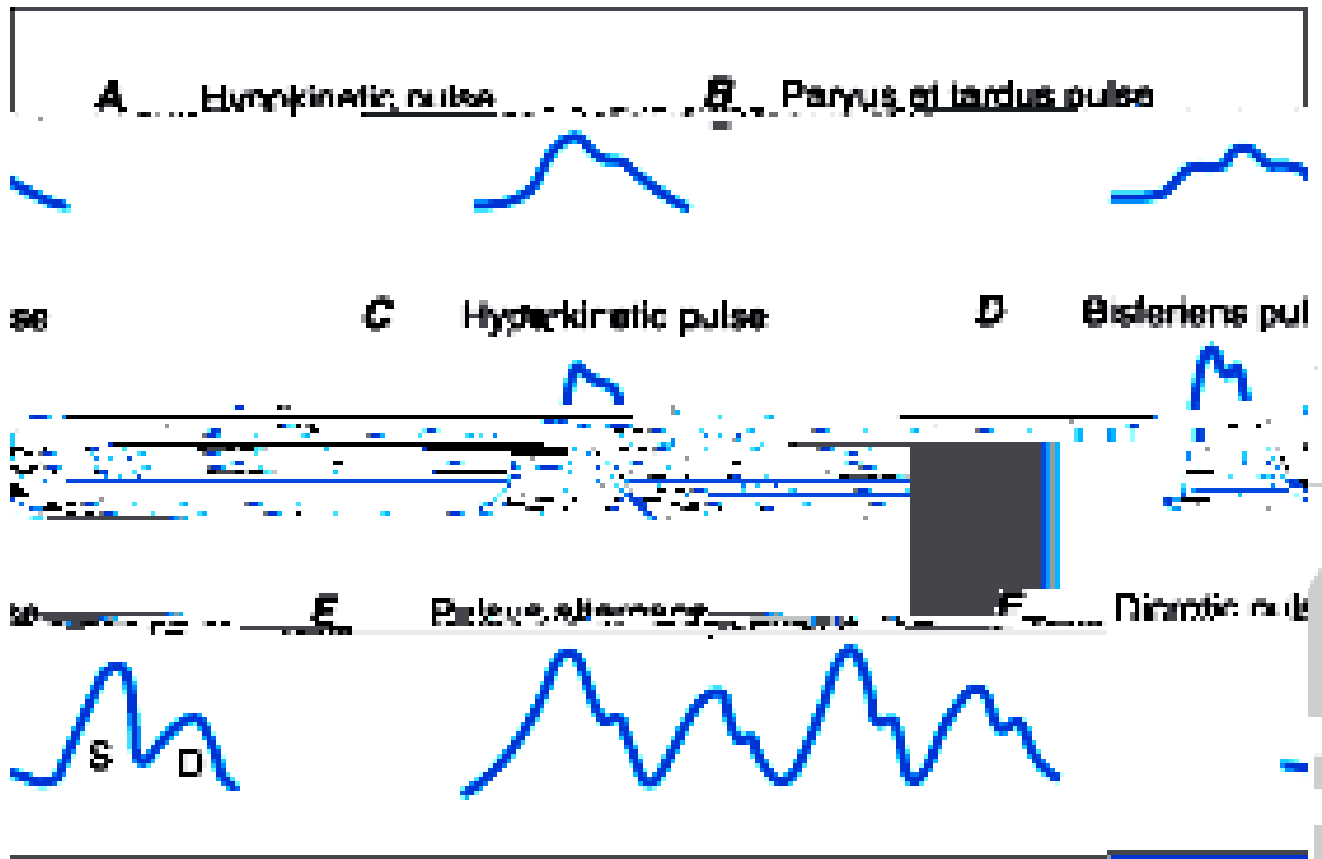
Irregularly irregular: e.g. atrial fibrillation

Character and Volume: best checked on carotid arteries

1. Observe for carotid pulsations.
2. Place fingers behind the patient's neck and compress the carotid on one side
3. Assess the following:
 - The amplitude of the pulse.
 - The contour of the pulse wave.
 - Variations in amplitude from beat to beat or with respiration.
4. Repeat on the opposite side.



Fig.4.1 Different characteristics of arterial pulse



Auscultation for Bruits

It is often checked in old aged patients. If present, it indicates carotid artery stenosis or atherosclerosis of the carotid artery.

N.B Do not be confused by heart sounds or murmurs transmitted from the chest.

Blood Pressure

The patient should not have eaten, smoked, taken caffeine, or engaged in vigorous exercise within the last 30 minutes. The room should be quiet and the patient comfortable.

1. Position the patient's arm so that the anticubital fold is level with the heart.
2. Center the bladder of the cuff over the brachial artery approximately 2 cm above the anticubital fold. *Proper cuff size is essential* to obtain an accurate reading

3. Palpate the radial pulse and inflate the cuff until the pulse disappears
4. Place the stethoscope over the brachial artery.
5. Inflate the cuff 20 to 30 mmHg above the estimated systolic pressure after the pulse disappears.
6. Release the pressure slowly, no greater than 5 mmHg per second.
7. The level at which you consistently hear beats is the systolic pressure.
8. Continue to lower the pressure until the sounds muffle and disappear. This is the diastolic pressure.
9. Record the blood pressure as systolic over diastolic (e.g. 120/70).
10. Blood pressure should be taken in both arms on the first encounter.
11. Maximum Cuff Pressure - When the baseline blood pressure is already known or hypertension is not suspected, it is acceptable in adults to inflate the cuff to 200 mmHg and go directly to auscultating the blood pressure. Be aware that there could be an auscultatory gap (a silent interval between the true systolic and diastolic pressures).
12. Pressure Differences - If there is more than 10 mmHg difference between the two arms, use the arm with the higher reading for subsequent measurements.
13. Systolic Pressure - In situations where auscultation is not possible, you can determine systolic blood pressure by palpation alone. Deflate the cuff until you feel the radial or brachial pulse return. The pressure by auscultation would be approximately 10 mmHg higher. Record the pressure indicating it was taken by palpation (60/palp).

Normal blood pressure in adults is Systolic: 90 – 140, Diastolic: 60 – 85 millimeter of mercury

Venous system

Jugular Venous Pressure (JVP):- is a reflection of the right atrial pressure and it is the most important part of venous system examination

1. Position the patient supine with the head of the table elevated 30 degrees

2. Use tangential, side lighting to observe for venous pulsations in the neck.
3. Look for a rapid, double (sometimes triple) wave with each heartbeat.
4. Adjust the angle of table elevation to bring out the venous pulsation.
5. Identify the highest point of pulsation. Using a horizontal line from this point, measure vertically from the sternal angle
6. This measurement should be less than 4 cm in a normal healthy adult

Tab. 4.2 Differentiation of the jugular and carotid pulse wave

	Jugular	Carotid artery
<i>Character:</i>	2 positive waves	1 wave
<i>Effect of respiration:</i>	↓ on the inspiration ↑ on expiration	No effect
<i>Venous compression:</i>	Easily eliminate pulse wave	No effect
<i>Changing position:</i>	More prominent when recumbent	No effect less prominent when sitting
<i>Abdominal Pressure:</i>	JVP more prominent (Hepatojugular reflux)	No effect
<i>Palpation :</i>	Not palpable	Palpable

Interpretation:

Normal: - is less than or equal to 4 cm of water

Elevated: - if greater than 4 cm of water above the sternal angle.

This indicates raised right atrial pressure which is most often found in right ventricular failure (dysfunction).

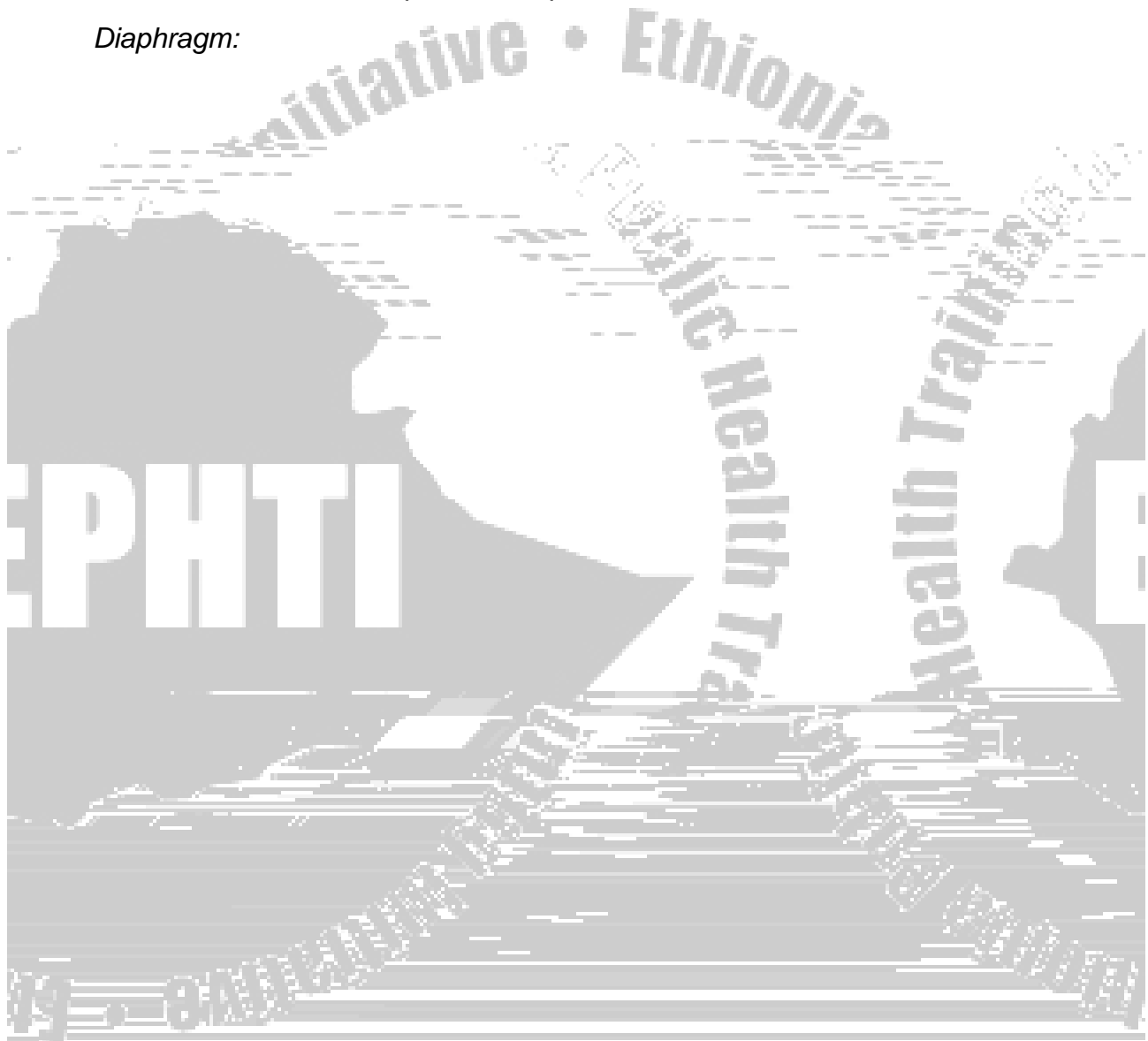


- **Amplitude:** thrusting if forceful or tapping if otherwise.

Percussion: Has little significance in precordial examination. It is done when one suspects dextrocardia or significant mediastinal shift.

Auscultation: The stethoscope has two parts:-

Diaphragm:



During auscultation focus on

1st Heart Sound, S₁. This signals the onset of systole and is caused by the closure of the mitral and tricuspid valves.

NB The 1st sound can be identified by palpating the carotid pulse while auscultating. The upstroke of the carotid pulse closely follows the 1st heart beat.

- **S₁ is loud in**
 - mitral stenosis
 - tachycardia
 - hyperdynamic circulation like e.g. anemia
- **S₁ is soft (Muffled)in:-**
 - mitral regurgitation
 - bradycardia and LVF

2nd Heart Sound, S₂. This separates systole and diastole. The sound is made by the closure of aortic and pulmonary valves. The aortic valve closes before the pulmonary valve and this **splitting of the second sound is heard particularly during inspiration**, as more blood is drawn into the right ventricle which is a normal phenomenon.

- **S₂ wide splitting occurs in**
 - right bundle branch block
 - pulmonary stenosis
 - Wide and fixed splitting (i.e. not varying with respiration) occurs when there is an atrial septal defect
- *A₂ is loud in systemic hypertension*
- *A₂ is soft in aortic stenosis*
- *P₂ is loud in pulmonary hypertension*
- *P₂ is soft in pulmonary stenosis*

3rd & 4th Heart Sounds

These are low pitched sounds. If either S_3 or S_4 is very loud it is often heard as gallop/triple rhythm.

3rd Heart Sound, S_3

This is produced by rapid ventricular filling and occurs in early-mid diastole i.e. soon after S_2 occurs normally in young fit adults with bradycardia e.g. athletes. It occurs abnormally in:

- patients with *heart failure*
 - left heart failure - S_3 heard best in mitral area
 - right heart failure - S_3 heard best in tricuspid area
- patients with *high ventricular filling pressure*
- *mitral regurgitation*

4th Heart Sound, S_4

This is an *atrial sound*, occurring just before S_1 . It is *always abnormal* as it represents atrial contraction against a stiffened ventricle e.g. due to *aortic stenosis* or *hypertensive heart disease*. It may also occur in heart failure.

Added Sounds

Opening snap may occur in *mitral or tricuspid stenosis*. Prosthetic valves make noises on opening and closing.

A *pericardial friction rub* is a leathery (rubbing) sound heard in systole or diastole, which suggests pericardial inflammation.

Pericardial knock is high pitched sound which is heard in early diastole. It indicates constrictive pericarditis.

Murmur

Murmur is abnormal sound due to turbulence of blood flow. It may be innocent (Physiologic) e.g. hyperdynamic states like anemia, pregnancy etc. or pathologic e.g. valvular lesions

Characterization of Murmur

- Timing: systole, diastole, continuous
- Point of maximum intensity (PMI)
- Direction of selective propagation (radiation)
- The character and quality of the murmur
- Intensity (grading)

Classification of Murmurs

Systolic murmurs

1) *Ejection systolic murmur* = *crescendo-decrescendo murmur*

This originates from the aortic outflow tract. It may be an innocent flow murmur which is common in childhood, pregnancy, anemia or pathological murmur as in

- *Aortic stenosis and Aortic sclerosis*
- *Hypertrophic obstructive cardiomyopathy*
- *Pulmonary stenosis*
- *Atrial septal defect*

2) *Pansystolic murmur*: It is of uniform intensity and merges with S₂. S₁ is often muffled. It is found in:-

- Mitral or Tricuspid regurgitation
- Ventricular septal defect

Diastolic murmurs

1) *Early diastolic murmur*: This is high-pitched and blowing. It occurs *due to*:-

- *Aortic or pulmonary regurgitation.* The aortic regurgitation murmur is usually soft and is best heard with the patient leaning forward and in expiration.

2) *Mid-diastolic murmur:* This is low-pitched and rumbling; it often starts after an opening snap. It is caused by:-

- *mitral stenosis* (common)
 - exhibits pre-systolic accentuation in sinus rhythm
 - amplified by rolling the patient into the left lateral position
- *Rheumatic fever*
 - thickens mitral valve leaflets
 - Is called *Carey Coombs' murmur*
- *aortic regurgitation*
 - regurgitant jet causes fluttering of anterior mitral valve cusp
 - Is called *Austin Flint murmur*
- *tricuspid stenosis* (rare)
- *large atrioseptal defect*

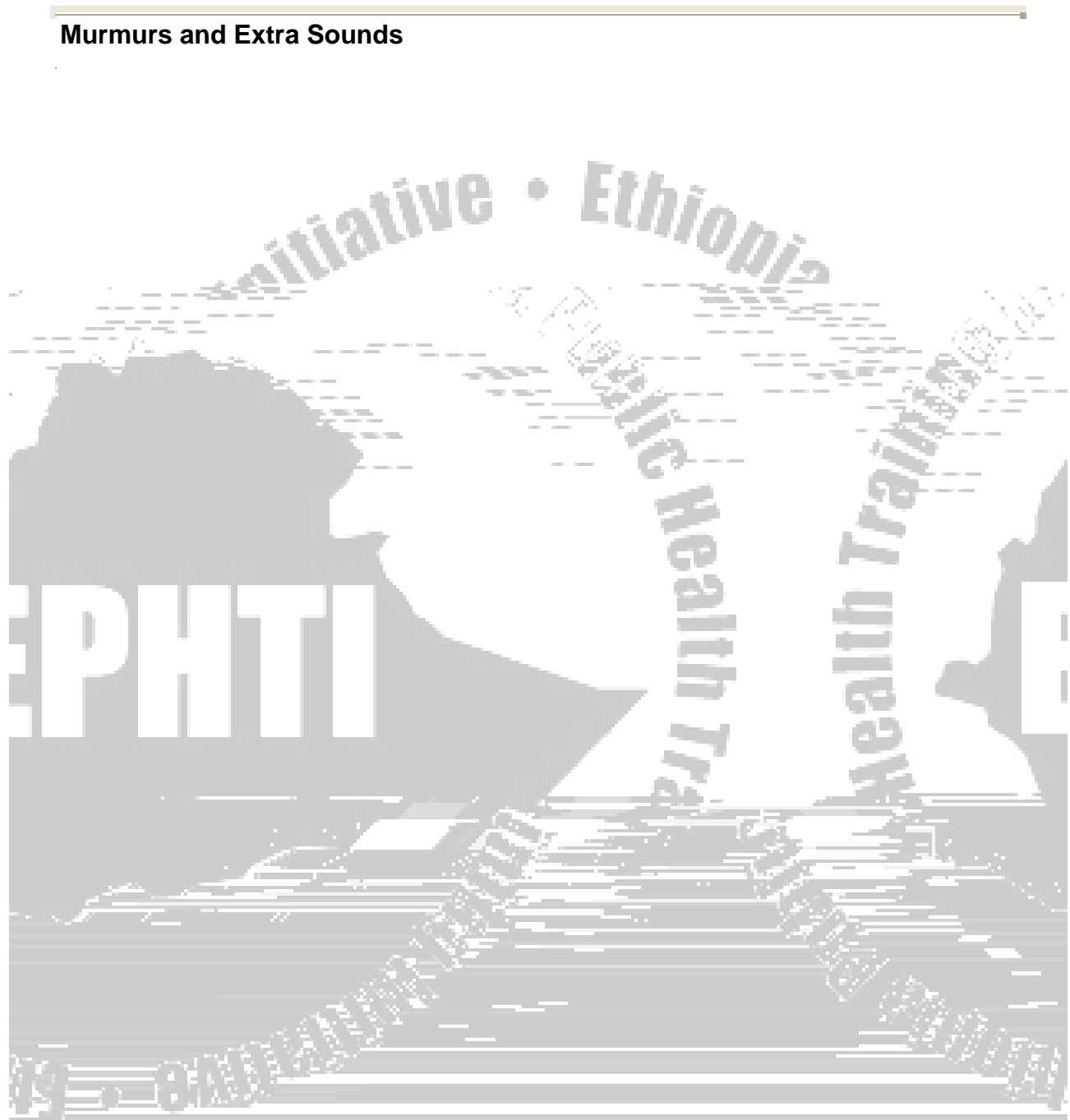
Other murmurs

1) *Continuous, machinery murmur of patent ductus arteriosus.*

2) *Musical or "mewing" murmurs* - characteristic of a *hole in an aortic valve cusp* due to endocarditis.

Record and report murmurs in the order of S1, S2, (S3), (S4), as well as the grade and configuration of any murmurs (e.g. "two over six" or "2/6", "pan systolic" or "crescendo").

Fig. 4.2 Interpretation of murmurs

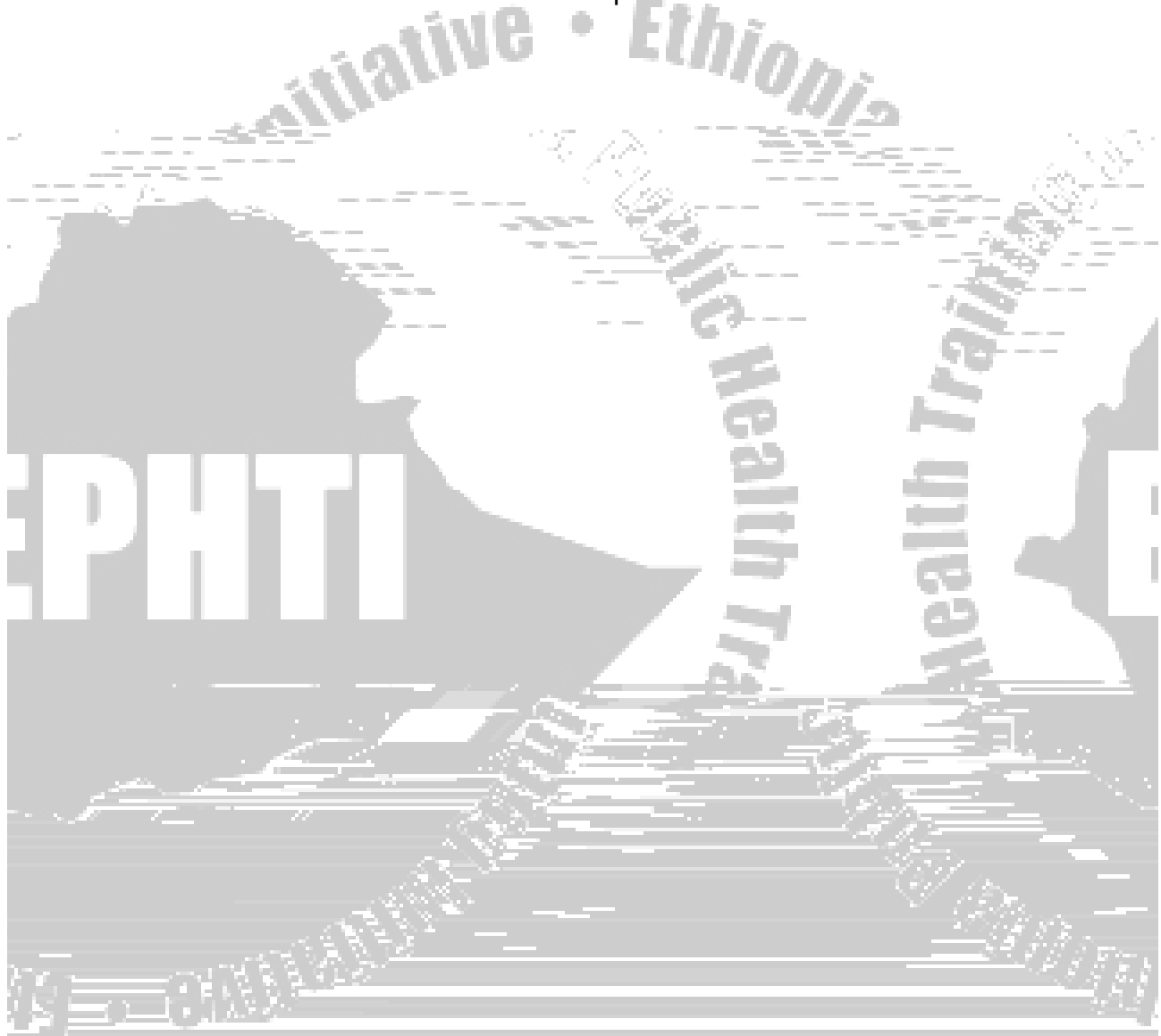


Tab. 4.3 Murmur Grades

Grade	Volume	Thrill
1/6	Very faint, only heard with optimal conditions	No
2/6	Loud enough to be obvious	No
3/6	Louder than grade 2	No
4/6	Very loud, heard in adjacent areas	Yes
5/6	Heard with the stethoscope partially off the chest	Yes


Review Questions

1. How can one differentiate between JVP and carotid pulsation?
2. How do you measure JVP?
3. Mention causes of systolic ejection murmur?
4. How should one characterize an arterial pulsation?



References

1. B. Bates, Guide to physical examination and history taking, 6th edition, 1995.
2. E. Brouwald, Harrison's Principles of Internal Medicine, 15th edition, 2001.
3. M. Swash, Hutchison's Clinical methods, 21st edition, 2002.



CHAPTER FIVE



- Type of diet causing dysphagia: to solid diet, liquid diet, or both
- Relation of the symptom with posture
- The duration and course of dysphagia
- The localization of the site by the patient
 - helpful in determining the site of esophageal obstruction
- Associated symptoms provide important diagnostic clues. These include
 - nasal regurgitation
 - tracheobronchial aspiration, choking with swallowing
 - weight loss
 - hoarseness of voice
 - hiccups
 - wheezing, chest pain, heartburn
 - history of prolonged nasogastric intubation
 - ingestion of caustic agents and previous radiation therapy
 - neurologic complaints e.g. weakness of extremities

Odynophagia

This is a condition where pain felt during swallowing secondary to either

Mucosal inflammation

- Reflux esophagitis
- Esophageal candidiasis

Mucosal abnormality

Nausea and vomiting

Nausea: denotes the feeling of an imminent desire to vomit, usually referred to the throat or epigastrium

Vomiting (emesis): refers to the forceful oral expulsion of gastric contents. The character of the vomitus offers clues to the diagnosis. Contents of the vomitus can be:

- undigested, or partially digested food
- bile
- blood (pure or altered)

Hematemesis: Is the vomiting of blood –pure or altered. It heralds the possible presence of bleeding into the gastrointestinal tract proximal to the ligamentum teres. If the rate of bleeding is fast, the color will be bright red. If the rate of bleeding is slow, blood mixes with the gastric secretions and becomes altered.

Coffee-ground vomiting: is the vomiting of precipitated blood clots and acid-degraded blood that produces a characteristic appearance when vomited (Dark blood or 'coffee grounds')

Projectile vomiting: Is vomiting without antecedent nausea. It suggests the possibility of a rise in the intracranial pressure or gastric outlet obstruction

Retching: Denotes the labored rhythmic contraction of respiratory and abdominal musculature that frequently precedes or accompanies vomiting

Regurgitation: Refers to the expulsion of food in the absence of nausea and without the abdominal, and diaphragmatic muscular contraction associated with vomiting

Indigestion (Dyspepsia):

A common complaint that generally refers to distress associated with eating. People use the term for many different symptoms including

- Heartburn
 - Sense of burning or warmth felt retrosternally that may radiate from the epigastrium to the neck
 - Inquire what brings on the discomfort and what relieves it.
- Excessive gas
 - Manifested by belching, abdominal bloating, distension or flatus
- Unpleasant abdominal fullness after meals of normal size or inability to eat a full meal
- Upper abdominal pain

The term is non-specific and may not have the same meaning for the patient and health professional. Thus, in approaching the patient with indigestion it is important for the health care provider to elicit first a precise description of this complaint. Having done that, it is important to determine

- The location and duration of the discomfort
- Temporal relation of the symptoms to the ingestion of food and
- The possible relation of the symptoms to the ingestion of specific types of food (e.g. milk, fatty foods, drugs)

Abdominal Pain

A variety of conditions produce abdominal pain and many of these conditions are non-specific in their presentation. As a result, the patient with abdominal pain is one of the more challenging diagnostic problems encountered in clinical practice. A patient's description of abdominal pain represents a subjective response to painful impulses, a response that is colored by a variety of psychological factors that influence the patient's description of it. Possible mechanisms of causation of abdominal pain include:

- **Visceral pain**
 - From both solid or hollow organs
 - Liver: secondary to capsular distention
 - Intestines, biliary tree: forceful contraction, distention
 - *Location*
 - Poorly localized, usually felt near the midline at a level corresponding to the structure involved
- Proximal to the Treitz ligament: in the epigastric region
- Between the Treitz ligament and the proximal two thirds of the transverse colon: in the umbilical area
- Distal to the junction between the middle two thirds and distal third of the transverse colon: suprapubic area
- *Quality*

Change in bowel habits

Some people would regard it as normal to open their bowels three or four times a day, while for others normality would be once a week. Certainly, the human body can function quite well at either extreme, but most people probably open their bowels every day or every couple of days. It is wise not to get obsessed by the need to open the bowels daily, but if one experiences a change of bowel habit that persists then he/she should seek the advice of a health care professional. It may be secondary to:

- mechanical bowel obstruction, benign or malignant cause
- Inflammatory bowel diseases
- Irritable bowel syndrome
- Medications
- Etc

Diarrhea: Is an abnormal increase in stool liquidity and frequency. The duration, frequency and contents (e.g. blood, mucus) of the loose stool plus history of accompanying tenesmus (intense urge, with straining but little or no result) should be described.

Constipation: Can be defined as two or fewer bowel movements per week and/or a sensation of straining, incomplete evacuation or hard lumpy stools in most occasions

Hematochezia: is the passage of bright red blood from the rectum with bowel movements. Blood in the stools may appear in four different ways.

- Mixed with feces
- On the surface of the feces
- Separate from the feces –either after or unrelated to defecation
- On the toilet paper after cleaning

Melena: Is the presence of black tarry stools as a result of blood degraded by intestinal enzymes. The blood usually originates proximal to the Treitz ligament

Icterus or jaundice: Is Yellowish discoloration of the skin and eyes. Associated symptoms can be seen such as:

- Change in the color of urine
- Change in the color of stools
- Itching
- Fever
- Right upper quadrant pain
- Loss of appetite
- Malaise
- Etc

PHYSICAL EXAMINATION OF THE GIS

THE MOUTH AND PHARYNX

Lips: Observe their color and moisture and note any lumps, ulcers cracking and scaliness.

Oral mucosa: Good light is required and the help of a tongue blade may be called for. Look for ulcers, white patches and nodules.

Gums and teeth: Inspect the color, gum margin and interdental papillae for swelling and ulceration, any missing, discolored, abnormally positioned or misshapen teeth

Roof of the Mouth: Inspect the color and architecture of the hard palate

The tongue and the floor of the mouth: Inspect the sides and undersurface of the tongue and the floor of the mouth. Note the color and texture of the dorsum of the tongue. Note white or reddened areas, nodules or ulcerations. Palpation of the tongue may be required for older people, especially those who are at a higher risk of developing cancer.


The Pharynx: With the patient's mouth open but the tongue not protruded, ask the patient to say 'ah'. This may allow you to see the pharynx well. If that is not the case, press a tongue blade firmly down the mid point of the arched tongue. Inspect the soft palate, anterior and posterior pillars, uvula, tonsils and pharynx. Note their

color and symmetry and look also for exudates, swelling, ulceration or tonsillar enlargement.

THE ABDOMEN

For recording and communication purposes, the abdomen may be divided into regions using

- Two lateral vertical planes passing from the femoral arteries below to the costal margin close to the tip of the ninth costal cartilage above
- Two horizontal planes, the subcostal and inter iliac, passing across the abdomen to connect the lowest points on the costal margins and the tubercles of the iliac crests respectively. (See figure 5.1.)



1. Right hypochondrium
2. Epigastrium
3. Left hypochondrium
4. Right lumbar
5. Umbilical
6. Left lumbar
7. Right iliac
8. Suprapubic
9. Left iliac

The abdomen can also be divided into four quadrants by imaginary lines crossing at the umbilicus.

- Right upper quadrant
- Right lower quadrant
- Left upper quadrant
- Left lower quadrant

Abdominal examination should be carried out in the presence of good light and with the patient fully relaxed. Full exposure from above the xiphoid process to the symphysis pubis is needed. The hands of the examiner should be warm and finger nails short.

While examining the abdomen, one has to follow the cardinal steps of physical examination, namely inspection, palpation, percussion and auscultation.

Inspection: The patient should be lying supine, with arms positioned loosely by his/her side. The examiner should make sure that there is a good light, that the room is warm and that his/her hands are warm. He/she should stand in the patient's right side, if he/she is right handed, and expose the area of the trunk between the part just above the xiphisternum and the upper thighs to expose the groins and genitalia.

Shape and symmetry: While inspecting for symmetry, the examiner should stand on the patient's feet side to check whether the abdomen is symmetrical or asymmetrical? If symmetrical, does it appear full (distended)? Distention may be due to

- fat
- fluid
- flatus
- fetus

It may also appear scaphoid (sunken) as in patients with wasting. If asymmetrical, note the position of any bulge. Check also if the flanks bulge or if there is flank fullness.

Umbilicus: The normal umbilicus is slightly retracted and inverted. If it is everted, an umbilical hernia may be present among other causes.

Abdominal wall movement: Normally, the abdominal wall rises gently with inspiration and falls with expiration. In generalized peritonitis, there will be a marked reduction in abdominal wall movement or it may totally be absent. Patients with obstruction of the pylorus for different reasons might exhibit visible peristalsis which would be seen as a slow wave passing across the abdomen from the left to the right hypochondrium. Obstruction of the small/large bowel is another cause of visible peristalsis.

Striae: are whitish or pink wrinkled marks on the abdominal skin. They are found in:

- Pregnancy (Striae gravidarum)
- ascites
- acute weight loss
- obesity

Wide purple striae are found in patients with Cushing syndrome and those with excessive steroid treatment.

Scars: Could be surgical or following other forms of trauma

Caput medusae: These are prominent superficial veins around the umbilicus representing opening up of anastomosis between portal and systemic veins. In cases of occlusion of the inferior vena cava, one may see dilated veins over the lateral aspects of the abdominal wall.

Linea nigra: This is pigmentation of the abdominal wall that may be seen in the midline below the umbilicus. It is a sign of pregnancy
The groins should finally be inspected for any swellings.

The Groins: The groin should be inspected and the patient is asked to cough. Both inguinal canals are inspected for any expansile impulse.

Palpation:

Palpation is the most important part of abdominal examination. It should be done with

- The patient relaxed and breathing quietly.
- The examiner being gentle and ask the patient if there is any area of pain and come to this region last while palpating.
- Palpation has to proceed in a logical sequence; one may start in the left iliac region; work anti-clockwise coming to the suprapubic area last.
- Initial light palpation followed by deeper palpation.

Light (superficial palpation)

Purpose: To identify:

- Abdominal tenderness

Try to assess the degree of tenderness

- Palpation over an area of mild tenderness just causes pain.
- Palpation over a moderately tender area causes the patient's abdominal muscles to tighten (guarding)
- Severe tenderness is associated with guarding, but in addition the sudden withdrawal of the manual pressure causes a sharp exacerbation of the pain (rebound tenderness)

with the right hand being moved more medially beneath the costal margin on each occasion. In minor degrees of enlargement, the spleen will be felt as a firm swelling with smooth, rounded borders. Factors that aid in differentiating an enlarged kidney from an enlarged spleen include

- the presence of a band of colonic resonance anterior to an enlarged kidney and not anterior to an enlarged spleen
- In case of the spleen, the direction of enlargement is generally downward and medially whereas in the kidney it is anteriorly and laterally.
- In reference to inspiration, the spleen moves downward; the kidney does not move.
- If the organ is bimanually palpable, it is a kidney since the spleen can't be palpated bimanually.
- The presence of a notch on the medial aspect of an enlarged spleen
- In ability to pass or insert fingers in the sub costal margin in case of the spleen

Liver: The examiner should place the right hand well below and parallel to the right subcostal margin. The patient is then asked to take a deep breath. The examiner at the same time tries to feel the liver edge as it comes down to meet his /her fingertips. If the examiner feels nothing abnormal, the process is repeated with his/her



Public Health Training
Initiative • Ethiopia
EPHTI
Public Health Training
Public Health Training
2019 • 8th Edition

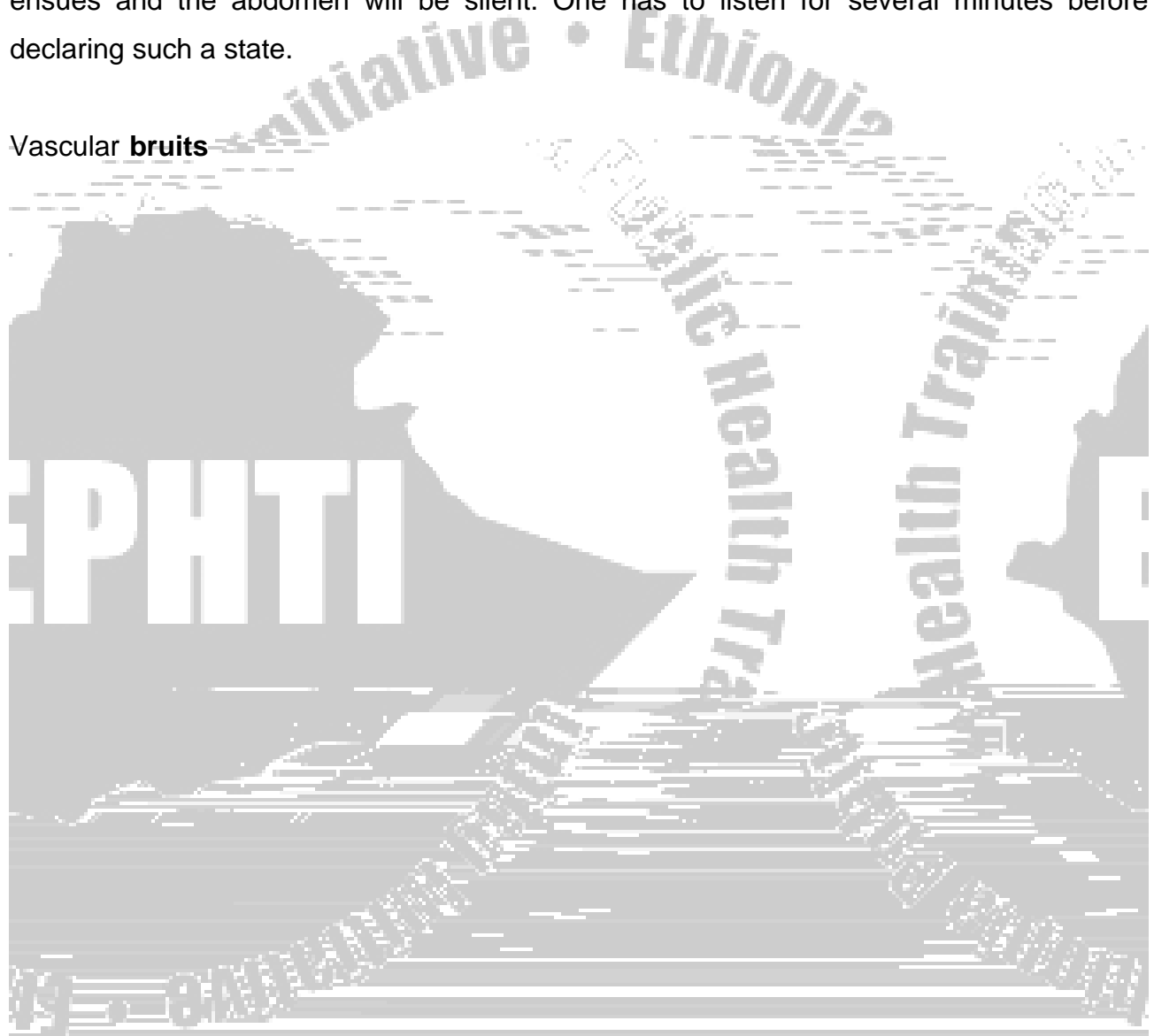


Public Health Training
Initiative • Ethiopia
EPHTI
Public Health Training
Public Health Training
2019 • 8th Edition

Physical Diagnosis

Normal bowel sounds are heard as intermittent, low or medium pitched gurgles interspersed with an occasional high-pitched noise or tinkle. Frequency of bowel sounds ranges from 5 to 34 per minute. Bowel sounds may be normal, increased or absent. In simple, acute mechanical obstruction, bowel sounds are excessive and exaggerated. In generalized peritonitis, bowel activity rapidly disappears and a state of paralytic ileus ensues and the abdomen will be silent. One has to listen for several minutes before declaring such a state.

Vascular **bruits**



and pressure applied firmly and slowly in a slightly backwards direction. After initial resistance the anal sphincter relaxes and the finger can be passed into the anal canal.

Anal musculature tone is assessed, and the finger rotated 360° in the canal to feel for any thickening or irregularity of the wall. The finger is then passed into the rectum and the rectal wall assessed with sweeping movements of the finger through 360° . With this maneuver, assess

- texture of the wall
- area of tenderness
- irregularity of rectal mucosa
- presence of any mass, ulcers
- mobility of the rectal mucosa

If you feel a mass at your fingertip, ask the patient to strain down. This moves the mass down by 2Cm or so.

In men, the rectovesical pouch, seminal vesicles and the prostate should be felt anteriorly. In women, the cervix is felt as a firm, rounded mass projecting back into the anterior wall of the rectum. On withdrawing the finger after rectal examination, look for evidence of mucus,

and can often lead to a diagnosis. the genitourinary tract is one of those affected by diseases and disorders related to age, sex, drug intake smoking and occupational hazards. history should be taken in detail. if the patient is female, age at menarche, number of deliveries complications at pregnancy or delivery should be documented.

A related group of signs and symptoms can arise in a patient with alterations of the sex organs. There is still unwarranted stigma and shame attached to sexually transmitted diseases. The interview and examination must be carried out in privacy and with confidentiality. As with other clinical problems, diagnosis is achieved by history, examination and relevant investigation.

SYMPTOMS OF GENITOURINARY DISEASES

Urinary Tract

Renal pain: This is pain arising from the kidneys and

- is usually felt at or below the costal margin posteriorly
- may radiate anteriorly towards the umbilicus
- is visceral pain produced by distention of the renal capsule
- is typically dull aching and steady

Ureteric pain: Results from sudden distention of the ureter and associated distention of the renal pelvis. It is severe colicky pain which originates in the costovertebral angle. It may radiate into the lower quadrant of the abdomen and possibly to the upper thigh and testicle or labium

Hematuria: Is the presence of red blood cells in the urine. It is a lab diagnosis.

Reddish discoloration of urine may be due to the presence of pigments in the urine. Bleeding can be continuous or intermittent and may be associated with pain. Therefore, inquire also about history of ingestion of beets or medications.

Oliguria: Denotes the passage of less than 400 ml of urine per day

Anuria: Is the complete absence of urine output. Retention of urine should be excluded before a patient is considered to have anuria.

Polyuria: Implies a high urine output. It is an arbitrary definition, on the basis of 24 hours urine output of more than 3L per day.

Urinary frequency: Is an abnormally frequent voiding. It is expressed in terms of day to night ratio. It results from polyuria or from a decrease in the functional bladder capacity as in bladder irritation or inflammation.

Nocturia: Implies the need to rise during hours of sleep to empty the bladder.

Dysuria: Is a specific form of discomfort arising from the urinary tract in which there is pain immediately before, during or immediately after micturation.

Urgency: Is the loss of the normal ability to postpone micturation beyond the time when the desire to pass urine is initially perceived.

Incontinence: Refers to an involuntary loss of urine that has become a social or hygienic problem.

Hesitancy: Is difficulty initiating the process of micturation.

Terminal dribbling: is difficulty of completing micturation in a clean stop fashion.

The Male Genital Tract

Urethral discharge: is nearly always a complaint of men, in the form of

- dripping
- staining of the underwear

The color, amount and duration of the discharge have to be ascertained. Commonest causes are sexually transmitted infections. It can be grouped as:

- Gonococcal urethritis
- Non-gonococcal urethritis

Genital ulcer: This may be recurrent, single or multiple, painful or painless. It is important to ascertain the evolution of the ulcer. Common causes include

- chancre of primary syphilis
- chancroid
- genital herpes

Other complaints

- History of sores, growths on the penis
- History of swelling or pain in the scrotum
- Past history of sexually transmitted infections
- History of sexual dysfunction

The Female Genital Tract

Vaginal discharge

- can be associated with itching
- the color, odor and amount should be characterized

Menstrual History: This part of history should be included. Various aspects should be considered including:

- Regularity
- Age at menarche (age at the onset of the first of the menstrual periods)
- Last menstrual period
- Length of time between periods
- How heavy is the flow
 - Estimate based on the number of pads or tampons used daily
- Bleeding between periods
- History of discomfort of pain during periods and severity, duration of the pain when present

Sexual History: The sexual history may be obtained after winning the patient's confidence. The history should include:

- Date of last sexual contact, details of contacts over recent months, possibility of homosexual and bisexual contact and the type of sexual practice are among the things to be elicited upon history taking.
- The use of condoms should be enquired into irrespective of whether the patient is using other methods of contraception.
- Psychosexual problems, including erectile dysfunction and premature ejaculation, can present as complaints during history taking.

Dyspareunia: Is pain on sexual intercourse. It can be superficial (i.e. pain in the vulvovaginal area) or deep (pain deep in the vagina).

Physical examination

Urinary system

Kidneys

- Inspect the flanks for bruising or swelling
- Assess each kidney for tenderness.
 - Have the patient sit, then place the palm of your hand over the costovertebral angle (CVA) and strike your hand with the ulnar surface of the fist of your other hand. Direct percussion with the fist over the CVA is also acceptable. The test should not cause any tenderness. If there is tenderness it can be indicated as costo- vertebral angle tenderness.
- Palpation of the kidneys may be carried out along with the abdominal examination.

Bladder

- Inspect the lower abdomen (suprapubic area).
- and palpate for enlarged bladder arising from the pelvis
- Look for enlargement or distention. Palpate for tenderness or rigidity.

The epididymis: Should be smooth, discrete, and non-tender

- In acute epididymitis, it is tender, swollen and may be difficult to distinguish from the testis.
- Palpate for the spermatic cord; look for varicocele

Prostate: Digital rectal examination will help assess the size, consistency, tenderness and invasion of the mucosa.

Female: Women are best examined in the lithotomy position.

- The vulva, labia minora and majora are examined for discharge, redness, swelling, excoriation, ulcers, warts and other lesions.
- The labia are separated to palpate the Bartholin's glands, which are not normally palpable.
- A bivalve speculum is then inserted and the color of the vaginal wall inspected and discharges, if present, characterized with respect to color, odor and consistency.
- The cervix is inspected for possible discharge, warts, ulcers and ectopy.
- Having removed the speculum, the urethral orifice is examined for discharge, inflammation and warts.
- Digital examination
 - Lubricate the index and middle fingers of your gloved right hand.
 - From a standing position, insert them into the vagina.
 - Note any nodularity or tenderness in the vaginal wall.
 - Palpate the cervix-note its shape, position, consistency, regularity, mobility or tenderness.
 - Palpate the uterus between the hand in the pelvis and your other hand placed on the abdomen.
 - Palpate the adnexae.
- Recto-vaginal examination

Review Questions

1. Describe the difference between visceral pain and parietal pain.
2. List down the factors that aid in differentiating an enlarged left kidney from an enlarged spleen.
3. What does the phrase rebound tenderness imply?
4. What is ballottement?
5. Mention the factors that aid in differentiating ureteric pain from a pain arising from the kidneys.
6. How can one elicit CVA tenderness?
7. What are the elements of a menstrual history?
8. How do you measure total liver span and
9. How do you differentiate ovarian cyst from ascites

REFERENCES

1. Fauci et al, Harrison's Principles of Internal medicine, 15th edition, 2000
2. Stein, Internal medicine, Fifth Edition, 1998
3. William N. Kelley, Textbook of Internal Medicine, 3rd Edition, 1997
4. Behrman et al, Nelson Textbook of Pediatrics, 16th Edition, 2000
5. Michael Swash, Hutchison's Clinical Methods, 21st Edition, 2002
6. Barbara Bates, A Guide to Physical Examination and History Taking, Sixth Edition, 1995
7. Norman L. Browse, An Introduction to the Symptoms and Signs of Surgical Disease, 3rd Edition, 1997

CHAPTER SIX

APPROACH TO GLANDS

EXAMINATION OF THE LYMPHO GLANDULAR SYSTEM

Objectives: At the end of this chapter the student should explain

1. The location and relevance of lymph nodes to various pathologies
2. The approaches in examination of lymph nodes
3. Techniques how to examine the breast and the axillae
4. And interpret the findings

Introduction

The lymph nodes are affected in many ways either directly or indirectly from diseases that originate in the lymphatic system itself or from any other organ system. The lymphatic circulation is an alternative circulation system in which heavy molecular weight substances are carried back to the circulation from tissues, and obviously, it also serves as a filtration in phagocytosis and immunological activities. The lymph nodes in most of the region are accessible to physical examination. The lymphatic drainage in a given tissue or organ system is initially to certain group of lymph nodes.

The accessible lymph node groups in our body for physical examination are:

Cervical lymph node groups

Axillary lymph node groups

Supraclavicular lymph node groups

Inguinal lymph node groups

Para aortic lymph node groups and others

Cervical lymph node group: are affected usually by neck and face pathologies. They are also involved in systemic illness such as lymphomas, tuberculosis, and pyogenic infections. The lymph nodes may be:

- Matted together e.g. Tuberculosis
- Discretely enlarged. Lymphomas
- Hard or soft in consistency depending up on the pathology
- Small or big size
- Associated with discharge etc

Patients complain of swelling in the neck, over the angle of the jaw or any where in the neck. The swelling could be painful, if the cause is inflammatory. It could be single swelling or occurring at different sites simultaneously.

Cervical lymph group are also divided as:

- Anterior
- Posterior
- Deep or Superficial.

Groups of lymph node found in the neck region are following (Fig.6.1)

- | | |
|------------------------|-------------------------|
| 1. Pre auricular | 6. Sub mental |
| 2. Posterior auricular | 7. Superficial cervical |
| 3. Occipital | 8. Supra clavicular |
| 4. Tonsilar | 9. Deep cervical |
| 5. Sub maxillary | 10. Supra clavicular |



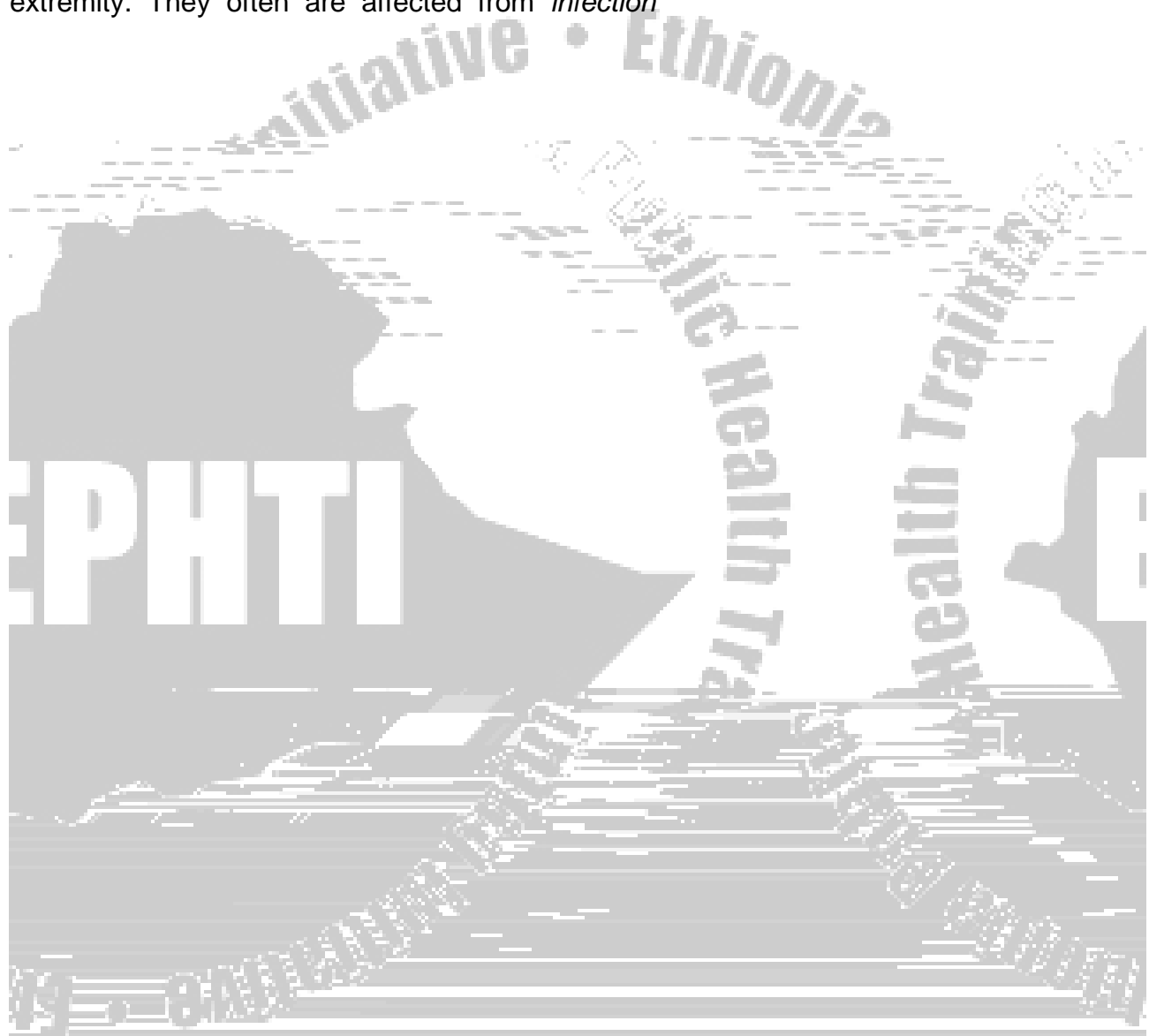
Fig 6.1

Each of these node groups are affected by different pathologies. It is therefore mandatory to be able to examine the nodes affected, as it is related to the understanding of the nature of the primary problem.

Examination of the axillary lymph nodes: the Axillary lymph node groups are the

The examination of lymphatic system of the axilla with out palpating the supraclavicular and infraclavicular lymph node groups will not be complete (see also breast examinations).

Examination of the inguinal lymph nodes: The inguinal lymph nodes are found along the inguinal canal. Most of them are palpable as they are check point for the lower extremity. They often are affected from *infection*



History

Ask the duration of the illness and any associated symptoms such as

- Pain
- Palpitation
- Dyspnea
- hot or cold intolerance
- Dysphasia
- Loss of appetite
- Recent fast growth
- Loss of weight
- Voice change (hoarseness)
- Anxiety or depression

Examination

The thyroid gland involves thorough examination of the gland, eye examination for related

then feel each lobe (right, left) by palpating the anterior boarder of the sterno-mastoid muscles by flexing the neck

measure the size

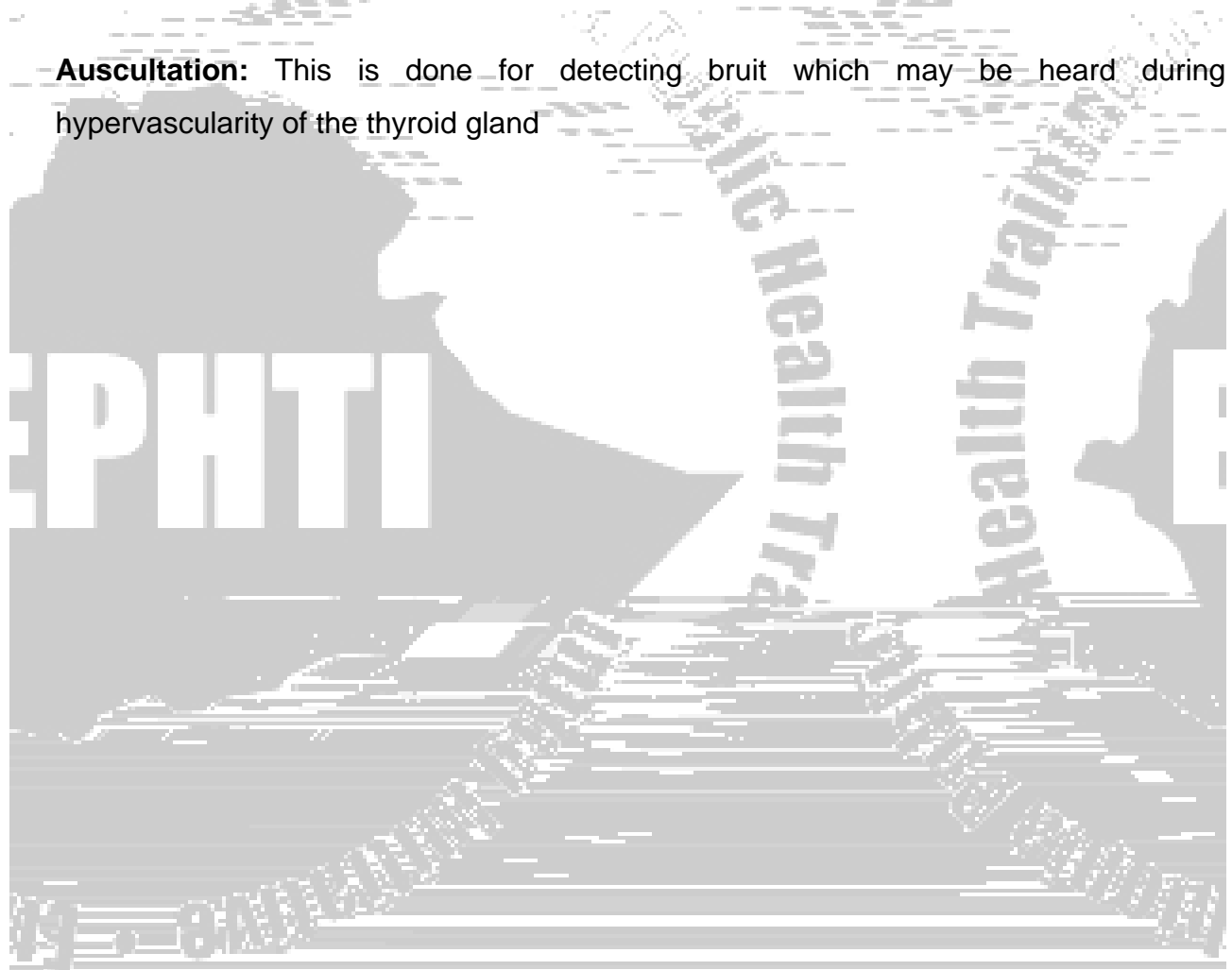
look for tenderness

assess for mobility and attachment

try to palpate the lower boarder of the thyroid gland and the trachea

Percussion: The upper part of the chest for possibility of retrosternal extension

Auscultation: This is done for detecting bruit which may be heard during hypervascularity of the thyroid gland






Fig. 6.3 Palpation of the thyroid gland from behind

This technique allows examination by relaxing the sterno cleido mastoid muscle

Eye examination:

Exophthalmus: protrusion of the eye ball, it is possible to see both the upper and lower limbus with the patient staring at the examiner

Lid lag: the upper eye lid lags while the eye ball moves down

Lid retraction: the lid is retracted living the eye ball exposed

Cardiovascular examination: This may reveal tachycardia, arrhythmia or murmur

Central nervous examinations: The following findings may be present:

- Hyperactivity may be observed
- sweating and warmness of the hands
- tremor of t

Examination of the Breast

Anatomy

The breasts are found on the anterior chest wall extending between 2nd and 6th rib longitudinally and from lateral sternal border to the anterior axillary line transversely.

Rest upon the pectoralis fascia, serratus anterior and abdominal wall muscles.

The axillary tail extends to the anterior axillary fold.

The lymphatic drainage of the breast is principally (> 75%) to the ipsilateral axillary lymph nodes.

History: Common breast complaints are:

- lump in the breast
- breast pain
-

Nipple discharge: Ask about:

- color (bloody, serous, purulent, milky, etc)
- spontaneous Vs non-Spontaneous
- unilateral Vs bilateral
- relation to menstrual cycle
- associated breast lump
- drug intake E.g. Oral contraceptives

Ask for any risk factor for cancer

- family history of breast cancer, 1st degree relation
- age at menarche (<12 years)
- age at menopause (>55 years)
- nulliparity
- history of contra lateral breast cancer

Ask for symptoms of metastatic disease (if cancer is suspected)

- bone pain or swelling
- cough, dyspnea, hemoptysis
- jaundice
- neurological abnormalities

Physical Examination

General principles

Should be done in a private place with g Tcni.s 0 Shoual EIs mor prifties j u c e r a

- elicit discharge from the nipple
- relate pain compliant to a specific breast finding
- detect skin changes
- detect enlarged axillary, supraclavicular or infraclavicular lymph nodes
- detect metastasis (If breast cancer suspected)

Inspection:

Stand in front of the patient. Look at the:

- size of breast
- symmetry and contour of breast
- nipple & areola for absence, symmetry, retraction, discharge
- skin for retraction, discoloration, “peau d’ orange” appearance nodules and ulceration
- Repeat the inspection with the patient raising her arms above the head.
- In apparent retractions and asymmetries may be evident now.

Palpation

- palpate with the palmar surface of your fingers
- roll the breast tissue between the chest wall and your hand
- palpate the whole breast quadrant by quadrant

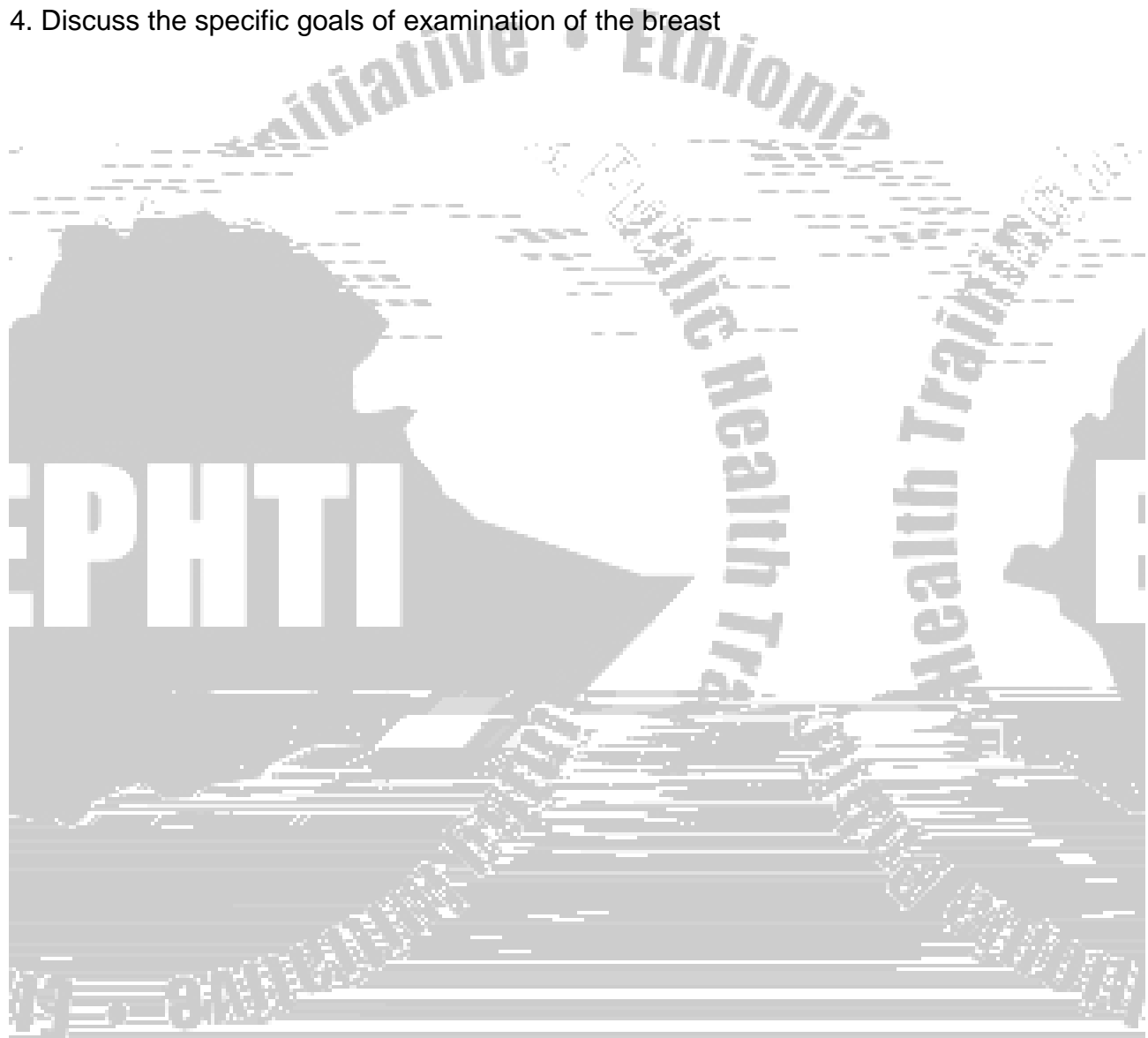
check for

- skin temperature
- consistency of breast, nodularity
- tenderness
- nipple discharge (expression)
- mass
 - discrete or indiscrete?
 - position in the breast
 - number
 - shape & size



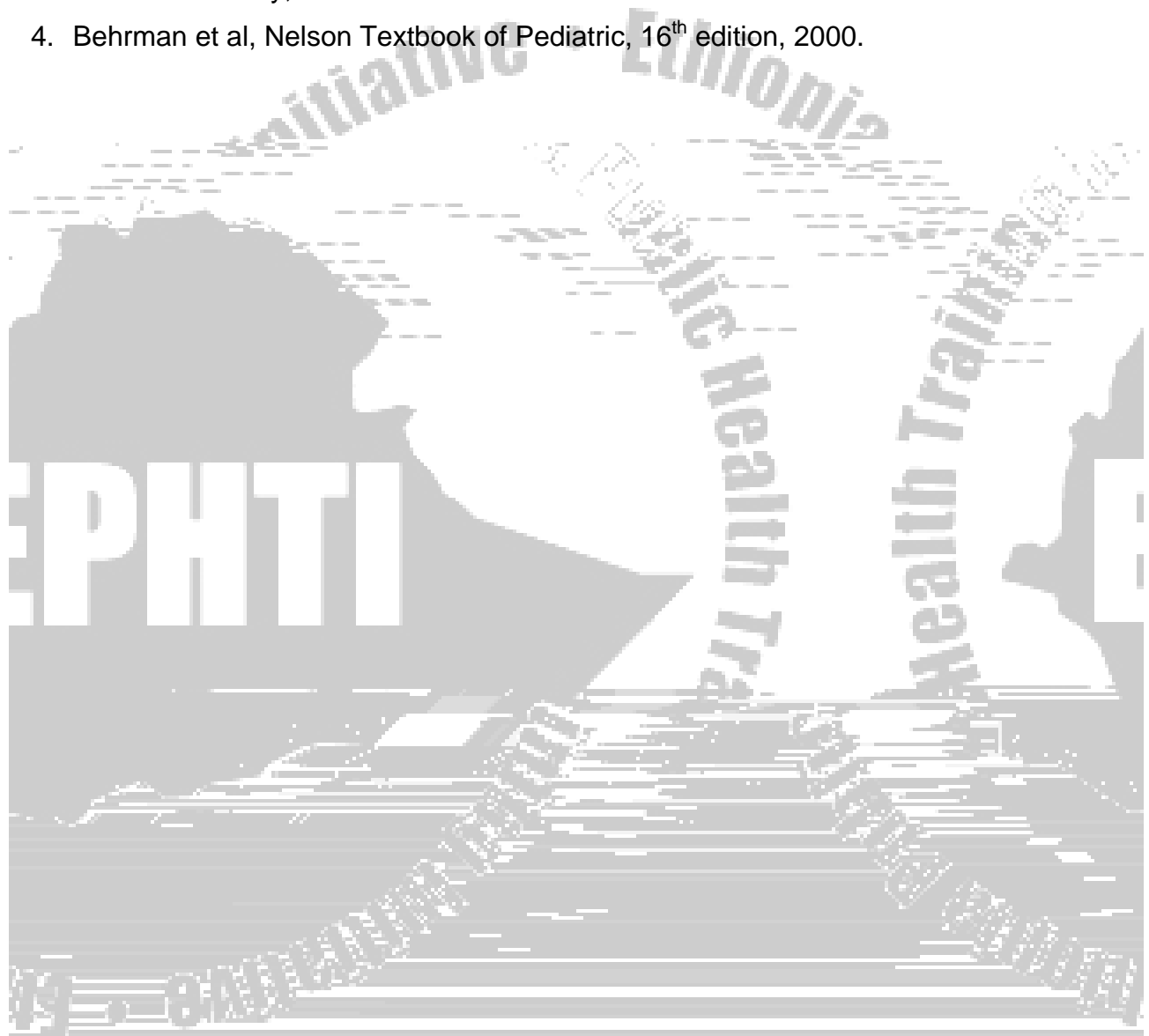
Review Questions

1. Describe some of the changes occur in the lymph nodes
2. List the different lymph node group of the cervical region
3. Discuss the common symptoms related to the thyroid gland enlargement
4. Discuss the specific goals of examination of the breast



Reference:

1. Fauci et al, Harrison's Principles of internal medicine, 15th edition, 2000.
2. Stein, internal medicine, Fifth edition, 1998.
3. William N. Kelley, Textbook of Internal Medicine 3rd edition 1997.
4. Behrman et al, Nelson Textbook of Pediatric, 16th edition, 2000.



CHAPTER SEVEN

APPROACH TO MUSCULOSKELETAL SYSTEM

LEARNING OBJECTIVES

After reading this chapter, the student should be able to

Explain the important aspects of history taking in relation to musculoskeletal disorders

Interpret specific history presented by the patient

Demonstrate basic skills of physical examination of the musculoskeletal system

Interpretation of physical findings related to the disorder

Practice techniques of examination of injured limb and interpretation of findings

INTRODUCTION

The musculoskeletal system is a system that comprises of the structures and joints necessary for body movement function. The major part of the examination is therefore centered on the joint but must often be extended to include the nerves and muscles which are responsible for movement.

This chapter reviews the principles of physical diagnosis related to the musculoskeletal system. It includes history and physical examination as both are needed in order to correctly evaluate diseases affecting the musculoskeletal system.

HISTORY TAKING

Successful treatment of any medical condition or a musculoskeletal disorder begins with an accurate history. The skill of interviewing patients to review the reason for presentation must be learned and constantly practiced by health workers. The history should be documented in chronologic order and include details of the current problem and all medical conditions before the present events.

Many relevant questions should be asked as needed to clarify a given symptom. When the complaints are few and localized, the history can be short e.g. a patient presenting after a knife injury to the tip of a finger, but a detailed history is necessary to understand the situation and render optimal treatment for other musculoskeletal conditions. The age and sex of the patient can be significant in understanding the nature of the disorder and planning the treatment.

If a patient complains of a thigh pain for example, the following questions should be raised and need to be understood in detail:

- Its specific location
- The character of the pain
- The frequency in which the pain occurs
- The duration and variation of the pain if any
- Aggravating or relieving factors
- Distribution or radiation of the pain to other locations
- Intensity and course should be determined.

Other questions should be included to know if the pain was caused by trauma. And if so, ask the following questions:

- What was the kind and degree of trauma?
- Was the trauma recent or old?

An effort should be made to determine the origin of the pain by its nature as there are varying kinds of pain that may be related to neurological, a peripheral nerve, muscle or a joint in origin.

After as much as possible information about the present complaint(s), has been obtained, the history can be completed by obtaining the following:

A review of the systems

Family and social history

The past history including a data about childhood illnesses, all immunizations, allergies and injuries

All medical, surgical and obstetric treatments...

Specific questions about the musculoskeletal system should include queries and elaborations on the following aspects:

Pain

Stiffness

Swelling

Buckling or the locking of a joint

Deformity

History of trauma including mechanism of injury

After completing the history, the examiner should put the patient at ease and explain on the procedure for physical examination. A complete examination, checking all the systems, is needed to correctly diagnose a condition.

PHYSICAL EXAMINATION

In practice, the area of interest for musculoskeletal examination is in joints and their supporting structures, the muscles, the nerves and the state of the bones of the body including the spine and how well all these structures function.

The major part of musculoskeletal examination is centered on the joints that trouble the patient, but the examination must often be extended to include the nerves and muscles which are responsible for movements of the joints, and some of the patient's other joints may also have to be checked to see if they are affected as well.

Respecting the dignity, the patient should undress and put on a loose dressing that allows the examination of the entire body if necessary. The physical examination requires close attention and the use of the examiner's senses to permit inspection, palpation, percussion, and auscultation. These are summarized in the musculoskeletal examination as **Look, Feel, Move, Measure** and the **Compare**.

Examination of the musculoskeletal system should begin by observing the general status of the patient on presentation. This may be helpful as the appearance of the patient and the way the patient moves can give some idea about the degree of apparent illness and whether or not in pain, about the nutritional and other state.



Fig. 1: Abnormal standing gait due to apparent shortening of the right lower limb. This can be noted during general inspection at the first contact of the patient.

The health worker has to note on the following conditions as part of the general observation:

Look for obvious deformities

A general description of the skin, including texture, scars and pigmentation

Overall gait pattern of the patient

Pattern of movements of the extremities

Fig. 2: *Deformity* (Angulation and shortening) of the left leg. This can obviously be noted during general observation of the extremity.




Fig. 3: Note the swollen left knee with poor quality of skin, scar and sinus on the medial aspect. This has also to be observed during general evaluation.

Following a general evaluation, the various systems may be examined. When examining the limbs and joints, comparison to the contra lateral side should always be done in order to appreciate the abnormalities.

MUSCLE EXAMINATION

When examining the muscle or muscle groups of interest, the following aspects need to be carefully assessed and determined:

The bulk of the muscle

Any fasciculation, fibrillation and tremor

Presence or absence of muscle tenderness

The tone of the muscle

The muscle power

Bulk

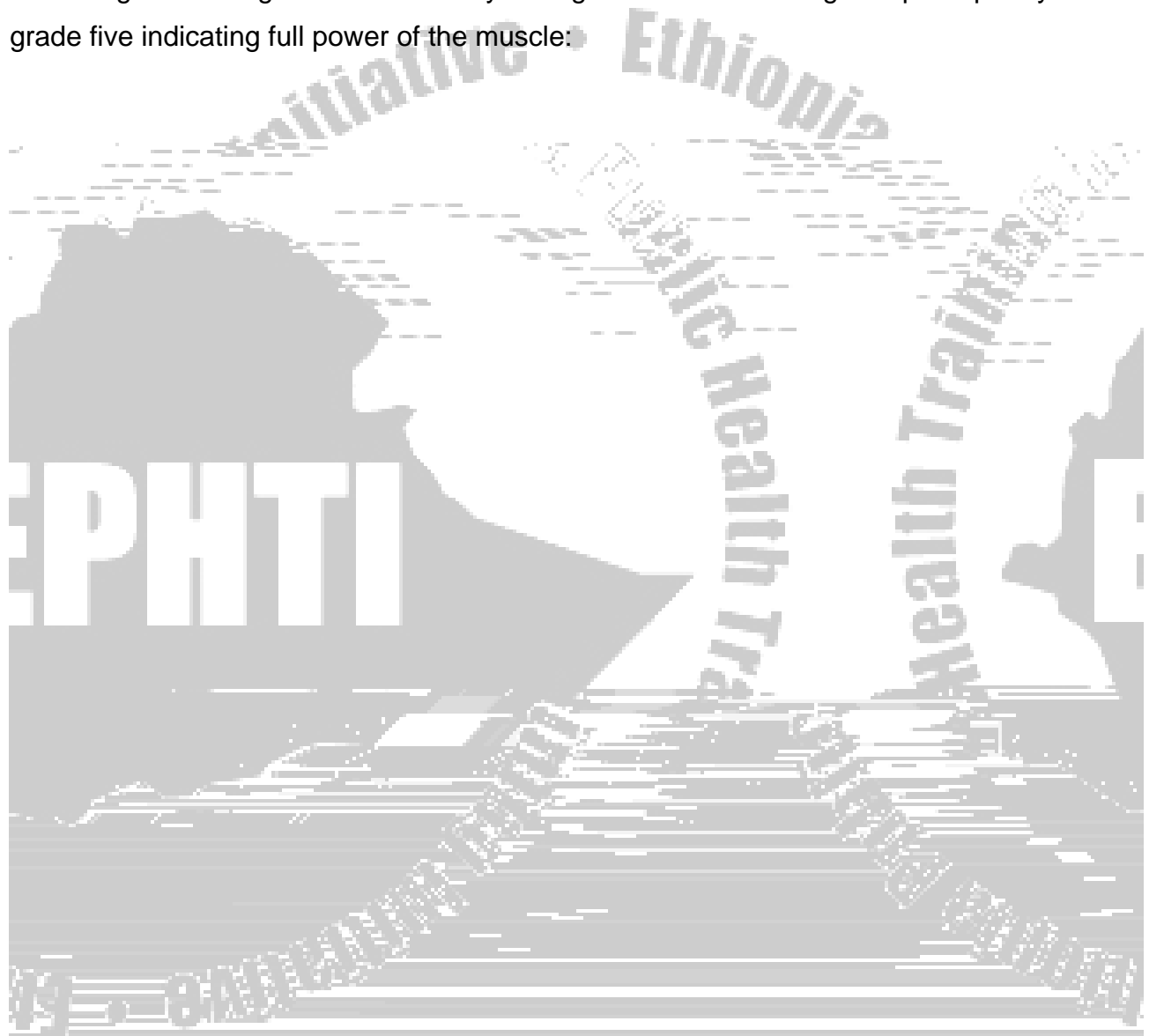
The muscle should be inspected for any change in bulk which indicates if there is loss of muscle volume or muscle atrophy. This can be either due to disuse because of various joint or muscle problems or loss of nerve supply to the muscle.

If there is a suggestion of muscle *atrophy*, compare each side of symmetric muscles by measuring the circumference at specific level. A constant point above or below a fixed point should be taken as a reference. For example, the circumferences of the leg can be measured by arbitrarily measuring 10 cm below the tubercles of the tibia, which allows a comparison in the muscles of the legs.



Power

During examination of a muscle, it should be tested for power which indicates about the strength of the muscle. As listed below, the muscle power can numerically be graded according to the degree of contractility with grade zero indicating complete paralysis and grade five indicating full power of the muscle:



During palpation of a joint, it should carefully be checked for warmth, swelling or tenderness and the findings should be recorded. Specific points where a mass may be palpable should be described. Joints should be tested for stability.

JOINT MOTION AND POSITION

The accepted method for joint motion is based on the principle of the neutral zero with the starting anatomic position of zero degree. In any event, the specific range of motion should be noted indicating the degree of abduction, adduction, flexion, and varus position for a given joint.

Some joints also have special directions of motion like rotation of the hip, pronation and supination of the elbow, eversion and inversion of ankle.

Moreover, data should be recorded for passive and active ranges of motion because both types of movement may provide important information in many instances. The general principles of measuring motion may be summarized as follows:

- 1) All motions should be measured by degrees from a neutral point zero.
- 2) The neutral point for a specific joint must be defined.
- 3) Compare to the motions in the joint of the opposite limb.
- 4) Angles should be measured with a goniometer or a protractor.
- 5) Motions below and above the a

Flexion= The act of bending, when the part distal to a joint bends



Fig. 5: *Adduction* of the hip joint
Note that the lower limb is brought close to the mid line of the body

Fig. 6: *Abduction* of the hip joint
Note that the lower limb is brought away from the mid line of the body



Fig. 7: *Inversion* of right foot

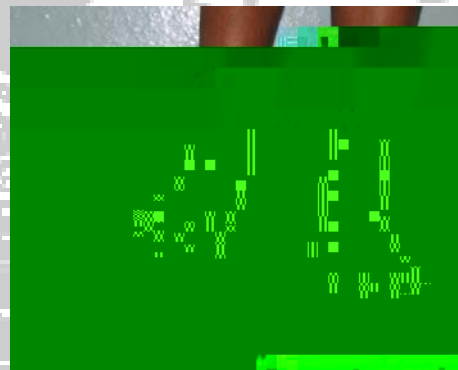


Fig. 8: *Eversion* of right foot



Fig. 9: *Extension* of right elbow



Fig. 10: *Flexion* of right elbow

Internal rotation= Rotation towards midline in a transverse plane

External rotation= Rotation away from the midline in a transverse plane

Pronation= Assuming a prone position, turning inward (palm and sole)

Supination= Assuming a supine position, turning upward (palm and sole)

Kyphosis= Increased rounding on the curve of thoracic spine

Lordosis= Anterior concavity of the lumbar and thoracic spinal curvature


a)

b)



Fig. 11: External (a) and Internal (b) *rotation* of the right hip joint

a)



b)



Fig. 12: Fore arm *supination* (a) and *pronation* (b) at the elbow joint

TECHNIQUE OF EXAMINATION

Joints possess a remarkable individuality and the techniques for examining one joint may vary from another. However, the common sequence listed below may be helpful and should be kept in mind.

1. LOOK: Look carefully at the joint paying particular attention to the following points:

a. Is there a **swelling?**

If so, is the swelling **diffuse** or **localized?**

If the swelling is diffuse, does it seem confined to the joint or does it extend beyond the joint?

Swelling confined to the joint suggests distension of the joint with:

Excessive synovial fluid (effusion)

E.g. Trauma

Non pyogenic inflammatory process

(Osteoarthritis, Rheumatoid arthritis...)

Blood (Hemarthrosis) from recent injury or coagulation defects

Pus (Pyoarthrosis) E.g. Acute pyogenic infection

Swelling extending beyond the confines of the joint may occur with major infections in a limb, tumors and problems of lymphatic and venous drainage.

If there is a localized swelling, note its position in relation to the underlying anatomic structures, as this may give a clue to its possible nature or identity.

b. Is there *bruising*?

If so, it might suggest trauma with a point of impact.

c. Is there any other *discoloration* or *edema*?

This might occur as a localized response to trauma or infection.

d. Is there muscle *wasting*?

This usually occurs as a result of disuse from pain or incapacity, or from denervation of the affected muscle.

e. Is there any alteration in *shape or posture*, or is there evidence of *shortening*?

There are many possible causes for each of these abnormalities including congenital abnormalities, post trauma disturbance of bone and destructive joint diseases.

e of0 Tcc

A diffuse increase in heat occurs when a substantial tissue mass is involved. It is seen most commonly in joints involved in pyogenic and non pyogenic inflammatory process.

A localized increase in temperature generally indicates an inflammatory process in the underlying anatomic structure.

Asymmetric coldness of a limb commonly occurs where the limb circulation is impaired. E.g. atherosclerosis

N.B:- Always bear in mind that false impression may be caused by effects of local dressing to the joint or a limb.

2. Is there

There are two forms of joint movement which need to be checked:

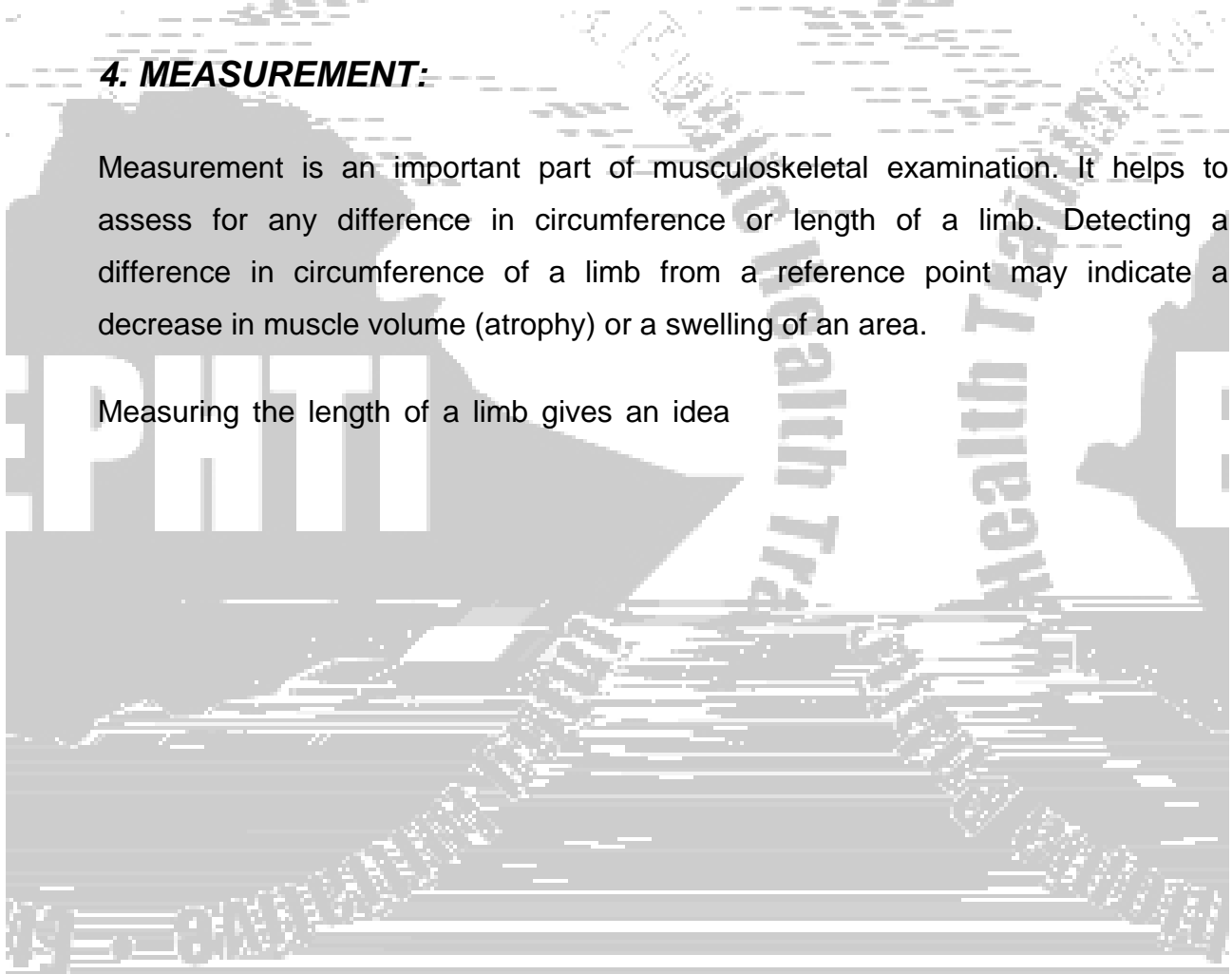
- 1) **Active** movement, where the patient moves the joint actively and
- 2) **Passive** movement, where the examiner moves the joint for the test.

Active movement may be reduced or absent in cases of pain in the joint or paralysis of muscles moving the joint. If the muscles controlling a joint are paralyzed, then the passive movement must be assessed. Occasionally, pain or other factors may restrict the active range of movements to a range less than the passive.

4. MEASUREMENT:

Measurement is an important part of musculoskeletal examination. It helps to assess for any difference in circumference or length of a limb. Detecting a difference in circumference of a limb from a reference point may indicate a decrease in muscle volume (atrophy) or a swelling of an area.

Measuring the length of a limb gives an idea



True Length: This is a measurement from two prominent points of the lower limb, e.g. the anterior superior iliac spine and the medial malleolus of the same limb in a supine position. The true length indicates a true shortening if there is a discrepancy. To know whether the discrepancy is from the femur or the tibia, one can check by measuring the real length or observing the legs in profile with the hips and knees flexed with the legs on the table.

a)

b)




Fig. 14: Measuring *Apparent* (a) and *True*

5. CONDUCTION OF SPECIAL TESTS

For most joints, there are a number of specific tests developed. These tests are especially helpful to test some particular aspects of that joint function. These include tests for the integrity of certain joint ligaments and for the examination of structures associated with the joint, e.g. the menisci in the knee. The anterior and posterior *Drawer's test* is an example of a special test for the knee joint to test the integrity of the anterior and posterior ligaments.

6. EXAMINATION OF RADIOGRAPHS

Radiographic examination may be done to confirm the clinical diagnosis and assess the severity of damage. The overall relationship of the important features and structures is made clear.

General inspection of the radiographs has to be done followed by shape size and contour of the bones. At the joints, look carefully for the following aspects:

- Alignment of the bony components if they are displaced or angled
- The joint surfaces if smooth or roughened
- Presence of any loose body in the joint

7. ARRANGING FURTHER INVESTIGATION

This stage of examination is not always required. But, in many cases, the additional tests serve to confirm a strong impression. There are various types of screening tests and the indication can be individualized.

EXAMINATION OF THE INJURED LIMB

Injury is one of the common presenting conditions to health institutions. Injury to a limb can occur either isolated to that limb or as part of poly trauma. A patient presenting with trauma should be carefully evaluated giving primary attention to the life threatening conditions. The limb should then be carefully checked looking for the following signs.

Swelling: If there is a swelling, check if it is localized and minimal or diffuse and gross.

Skin color: If there is abnormal darkening, it may indicate ischemia.

Skin damage: If there is damage to the skin, check if it is superficial or deep and if there is any necrotic skin.

Sign of fracture: Look for the various signs of fracture. There can be specific and non-specific signs for fracture. Fracture is obvious if the following signs are detected:

Deformity, which may be in a form of shortening, angulation or abnormal rotation of a bone or a limb

Visiy1

Review Questions

1. Describe some of the symptoms related to specifically to muskuloskeletal system
2. discuss the cardinal steps of muskuloskeletal examination
3. Explain the differences among real length, true length and apparent length



Reference

1. Barbara Bates: a Guide to Physical Examination and History Taking, 6th edition, 1995.
2. Ronald Mc Rae: Clinical Orthopedic Examination, 3rd edition Churchill Livingstone, 1990.
3. Post, Melvin: Physical Examination of the Musculoskeletal System Chicago yar Book Medical Publishers INC, 1987.
4. Beetham, William P et al: Physical Examination of the Joints Philadelphia W.B. sounders Company 1965.
5. Browse, Norman L: An Introduction to the Symptoms and Signs of Surgical Diseases, 1990.

CHAPTER EIGHT

APPROACH TO INTEGUMENTARY SYSTEM

Objectives

At the end of this chapter, the student should be able to

1. explain common symptoms of diseases affecting the integumentary system
2. explain how to perform physical examination of the integumentary system
3. explain what primary and secondary skin lesions are

INTRODUCTION

The integumentary system consists of the skin and the skin appendages (hair, sebaceous glands, sweat glands and the nails). Its functions include

- Protection: barrier against the outside
- Protection against dehydration
- Body temperature regulation
- Cutaneous sensation
- Metabolic functions
- Blood reservoir
- Excretion

SKIN

The skin is the largest organ of the human

History


As in other branches of medicine, a complete history should be obtained to emphasize the following features.

- Evolution of lesions
 - Site of onset
 - Manner in which eruption progressed or spread
 - Duration
 - Periods of resolution or improvement in chronic eruptions
- Symptoms associated with the eruption
 - Itching, burning, pain and numbness
 - Relieving/aggravating factors for the symptom, if any
 - Time of day when symptoms are most severe
- Current or recent medications
- Associated systemic symptoms (e.g. malaise, fever)
- Ongoing or previous illnesses
- History of allergies
- Presence of photosensitivity
- Social and occupational history
- History of recent travel
- Sexual history
- Systemic review

Physical Examination

- The whole skin should be exposed preferably in natural light.
- Sometimes a magnifying lens is useful.
- In doing physical examination of the skin, one starts by inspecting the color of the skin and notes if pallor, abnormal redness of the skin, jaundice, increased pigmentation etc. moisture, texture, and turgor are present.

To aid in the interpretation of skin lesions, a variety of descriptive terms have been developed. These include terms that describe the primary lesion itself (**primary skin lesions**) or terms that are used to describe alterations in the primary skin lesions secondary to factors such as in



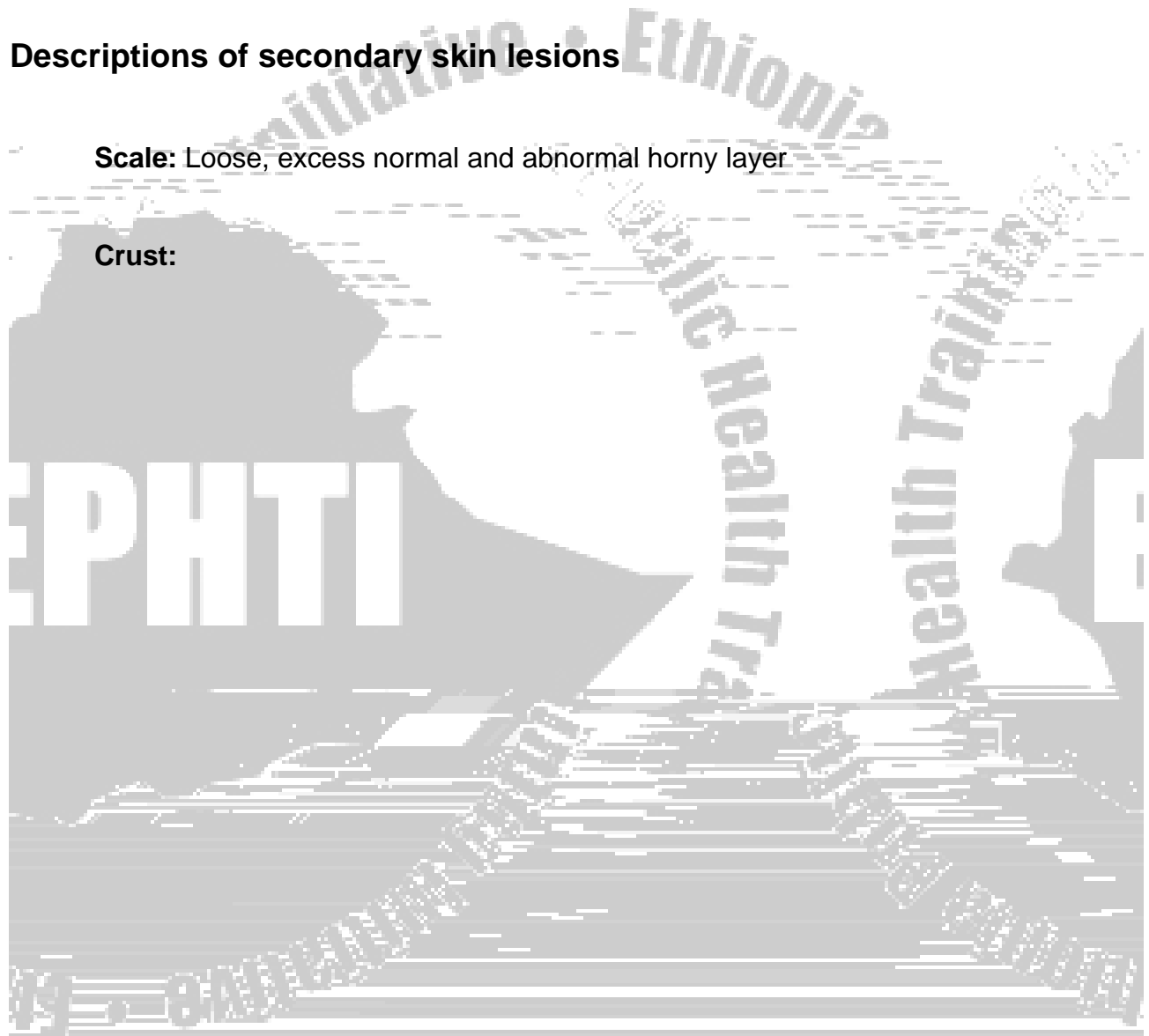
Wheal: Raised, erythematous papule or plaque, usually representing short-lived dermal edema

Telangiectasia: Dilated, superficial blood vessels

Descriptions of secondary skin lesions

Scale: Loose, excess normal and abnormal horny layer

Crust:



Primary lesions are usually more helpful for diagnostic purposes than secondary lesions.

Assessment of the morphology of skin lesions requires visual and tactile examination. Palpation should be done to determine the surface of the skin lesion, its thickness and whether the lesion blanches with pressure or not. Universal precaution protocols against transmission of contagious illnesses should be observed while carrying out palpation.

Distribution of lesions often correlates highly with diagnosis. The skin surface should be looked at to describe the distribution of the lesions, as should mucosal surfaces for the presence or absence of lesions. One has to consider the following factors in doing so.

- Is the eruption symmetrical or asymmetrical?
- Is it centrifugal (concentrated away from the center) or centripetal (concentrated around the center)?

Finally, in describing a skin lesion, one begins with distribution, then configuration, color, secondary changes and primary changes. For example, scabies may be described as a skin disorder involving volar wrist, the inter-digital areas, and the elbows symmetrically with excoriation on the basis of a popular, nodul



Hypertrichosis: Represents excessive hair growth at inappropriate locations. This can be localized or generalized; or permanent or transient.

Hypotrichosis: Represents deficient hair growth.

NAILS

Nails are specialized protective epidermal structures that form convex translucent, tight .72n

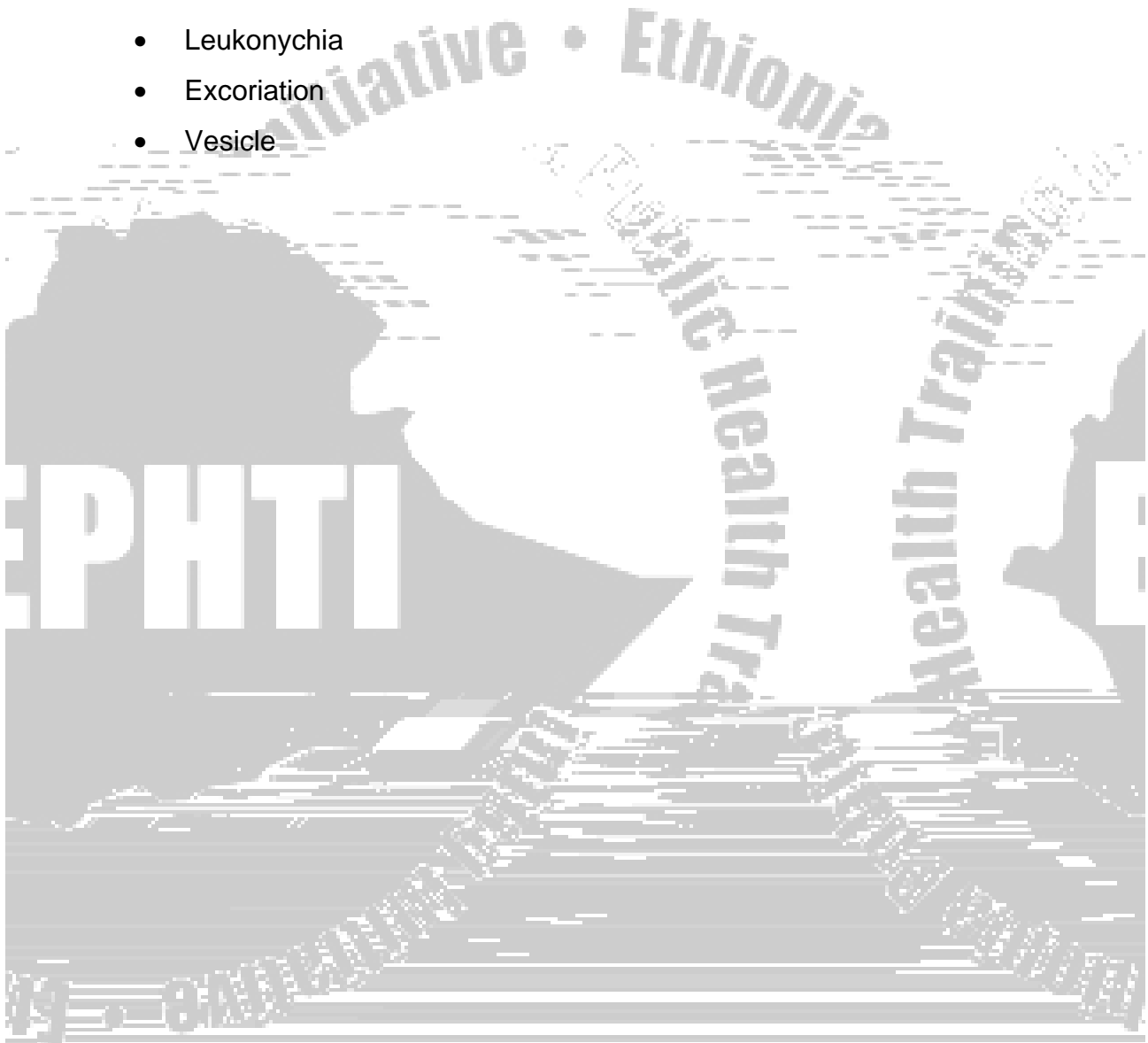


Clubbing of the nails

- Is characterized by swelling of the distal digit, an increase in the angle between the nail plate and the proximal nail fold (Lovibond's angle) to greater than 180° , and a spongy feeling when one pushes down and away from the distal inter phalangeal joint because of an increase in fibro vascular tissue between the matrix and phalanx. Common Causes of Clubbing of the nails include:
 - Congenital heart diseases(cyanotic type)
 - Respiratory Causes
 - Bronchiectasis
 - Lung abscess
 - Lung cancer
 - Pulmonary fibrosis
 - Gastrointestinal Causes
 - Crohn's disease
 - Celiac disease
 - Cirrhosis
 - Cystic fibrosis

Review Questions

1. What is the difference between primary and secondary skin lesions?
2. Outline important aspects of history in skin examination.
3. Define the following terms.
 - Leukonychia
 - Excoriation
 - Vesicle



REFERENCES

1. Fauci et al, Harrison's Principles of Internal medicine, 15th edition, 2000
2. Stein, Internal medicine, Fifth Edition, 1998
3. William N. Kelley, Textbook of Internal Medicine, 3rd Edition, 1997
4. Behrman et al, Nelson Textbook of Pediatrics, 16th Edition, 2000
5. Michael Swash, Hutchison's Clinical Methods, 21st Edition, 2002
6. Barbara Bates, A Guide to Physical Examination and History Taking, Sixth Edition, 1995
7. Norman L. Browse, An Introduction to the Symptoms and Signs of Surgical Disease, 3rd Edition, 1997



CHAPTER NINE

APPROCH TO SPECIAL EXAMINATIONS

In any thorough examination of the patient it is necessary to be able to make a primary assessment of special structures such as the Ear, nose and throat (ENT), the eyes, the skin and the mental and behavioral function (psychiatry). Therefore the objective this lecture is to outline important steps in the examination of t



Protection for the eyes:

- The conjunctiva is a thin mucous membrane covering the outer surface of the eyeball and inner surface of the eyelid that protects cornea from drying and infection.
- Eyelid covers the eyeball protecting it from injury and keeping it moist.
- The Orbicularis oculi close the eyelid and the Levator oculi muscles open it.
- These are supplied by the facial nerve and oculomotor nerves respectively.
- The lacrimal apparatus consisting of glands producing tear and canaliculi transporting this to the lacrimal sac at the medial corner of the eye.
- Tear coming from the punctum (opening of lacrimal canaliculi) washes and drain the eyes.

HISTORY TAKING

Symptoms of eye disease

ALTERATION OF VISION

- 1-Photophobia is discomfort caused by brightness in inflammation of the cornea.
- 2-Distortion of vision occurs due to lesions in the macular area of retina.
- 3-Floaters are formed by small opacities in the vitreous body.
- 4-Visual field defects due to retinal optic nerve or visual pathway diseases.

PAIN IN THE EYE

- 1-Irritation of conjunctivitis
- 2-severe pain of iritis, corneal ulcer or raised ocular pressure
- 3-Choroiditis and optic neuritis give dull pain

OTHER SYMPTOMS

- 1-discharge
- 2-diplopia
- 3-headach

EXAMINATION OF THE EYE

Components of the eye examination

1. Visual acuity
2. Visual field
3. Color vision
4. Fundus
5. Front part of the eye
6. Pupils

VISUAL ACUITY

- Testing of acuity should be done separately for each eye.
- The Snellen's chart is first used.
- If the patient can't see anything on the Snellen's chart use hand movement.
- If the patient can't see any hand movement check for the light perception.
- If light perception also not possible a patient should be made to look through pinhole to rule out refractive error before concluding eye disease (blindness)

SNELLEN'S CHART

There are seven lines on the chart with numbers 60, 36, 24, 18, 12, 6,

These numbers are the distance that a person with normal sight should be able to see (for example a normal person should be able to see the letter in the first line marked 60 at 60 meters distance from the chart.)

A person is made to stand *six meters* from the Snellen's chart

If he can identify letters only in the first line, marked 60, then his vision is 6/60

If he identifies up to the third line his vision is 6/24, if he is able to read up to the bottom his acuity is said to be 6/6.

VISUAL FIELD

The confrontation test is very easy to determine the visual field defects by comparing it with that of the examiner.

- 1-Patient and examiner sit facing each other at not more than one meter apart.
- 2-When testing the left eye the right eye of the patient and the left eye of the examiner should be closed.
- 3-The patient and the examiner should then be looking straight into each others eyes
- 4-Holding your finger equidistant between you and the patient, ask him to say when the fingers move
- 5-If you can see them but not the patient then he has a field defect.
- 6-By moving the finger in different quadrants, a simple visual field can be plotted.

COLOR VISION

Special chart called Ishihara's chart is require to perform the test. Since specific color vision defects not common, this is rarely necessary. A simple color test is to compare color perception of one eye with the other. Hold a small red target in front of patient with one eye closed then the other eye, if it is much less brighter in one of the eyes then optic nerve that eye is affected.

- The magnification potential of the ophthalmoscope helps not only in fundus examination but also in examining the front of the eye for very small lesions not seen with the naked eyes (cornea, lens, eyelids, and conjunctiva)
- The fundus therefore extremely useful where essential but sophisticated slit lamp and skill for operating it is unavailable

EXAMINATION OF THE FUNDUS

- Requires the use of the ophthalmoscope.(see note below on ophthalmoscope)
- Examination should explore the following areas of the retina.
 - 1-Optic nerve head and vessels coming out of it give the optic disk.
 - 2-Macula
 - 3-The periphery of the fundus

Fundoscopy procedure

- 1-to examine the right eye hold the ophthalmoscope in the left hand and the patient's head in the left
- 2-Rest your right hand against the patients cheek so that the ophthalmoscope is just in front ,but not touching the patient's eye.
- 3-Bring your right eye up to the sight hole, and look down into the patient's eye
- 4-Normally you should be able to examine the patient's fundus clearly without any correcting lens in the ophthalmoscope
- 5-If the fundus is not clearly seen then there is a refractive error corrected by using the suitable diopter or there is opacity in the cornea, lens or vitreous body.

Steps in examination of the fundus:

- 1-The disk is located by following the vessels until their apparent convergence into the disk
- 2-Look at the disk margins (clearly delineated or blurred as in papilledema)
- 3-Is the disk yellowish orange? (Whitish in optic atrophy)
- 4-Look and compare venous to arterial diameters
- 5-Look for white areas of infarction or exudation
- 6-Look for red areas of hemorrhage

EXAMINATION OF THE FRONT OF THE EYE

Cornea, lens and vitreous humor are best examined by the slit lamp. A hand-held convex magnifying lens with a separate light-source can be used. Ophthalmoscope can also be used as a lens with built-in light source.

Using the ophthalmoscope in examination of the front of the eye:

- 1-Hold the ophthalmoscope as in retinal exam
- 2-Diopter however should be adjusted at 15+ to 20+.
- 3-Get a clear view of the conjunctiva, cornea Iris, or lens
- 4-To focus move back and forth from the eye or use a different positive diopter

Cornea, eyelid and vitreous humor

To get a general view of the above structures:

- 1 -Use a weak lens of about 5 diopters
- 2 -Hold it at about 20cm from the eye
- 3 -Then bring it slowly closer to the patient's eye while looking through the ophthalmoscope

To get a magnified view of the cornea and lens:

- 1-Use strongly positive diopters like 20+
- 2-Hold it close to the patient's eyes.
- 3-Will reveal as small lesions as the microfilaria.

Steps in examination of the upper Tarsal conjunctiva

- 1-Ask patient to look down
- 2-Hold the upper lid eyelashes between the finger and the thumb of one hand and gently stretch the eyelid
- 3-With the other hand rest a glass rod on the upper margin of the tarsus plate, so that there is slight pressure.
- 4-Flik the tarsal plate inside out

Examination of the pupils

The shape of the pupils should be observed, for instance it becomes irregular in Iritis. The pupillary size and reactivity to light should be observed. The patient should look into the distance while the light reaction is being checked because of the effect of accommodation reflex on the pupils' size.

Causes of Dilated Pupils

- 1-Mydriatic
- 2-Parasympathetic palsy
- 3-Glaucoma
- 4-Trauma

Causes of Constricted Pupils

- 1-Miotic
- 2-Sympathetic nerve palsy
- 3-Iritis

Terminologies

- *Direct* light reactivity-the normal pupils react to light by constriction.
- *Consensual* light reactivity –the normal pupils constrict in reaction to light shone on the other eye.

- *Accommodation* reflex-the pupils constrict when focusing on near object soon after looking into the distant.
- *Afferent defect*-fibers from retina through optic nerve rare damaged so that there is no sensory input.
- *Efferent defect*-the motor fibers in the oculomotor are damaged so that there is no motor output to the constriction muscles.

Clinical findings in afferent defect (optic nerve palsy)

Size of pupils is Equal.

Pupil of affected side will not react to light.

The unaffected eye will not react consensually.

When light is shifted to the unaffected eye it reacts vigorously.

The consensual reaction of the affected eye is also vigorous.

Clinical findings in efferent defect (oculomotor palsy)

-Size of the pupils is Unequal, with affected side dilated.

-Affected eye will not constrict, normal side react.

-When light is shone into affected eyes the pupil on the normal eye constrict.

When the light is shifted to the normal es

TheEar s

Ear Canal and Drum



Some pathologic findings

- -Non tender nodular swellings covered by normal skin deep in the ear canals suggest exostoses. These are nonmalignant over-growths, which may obscure the drum.
- Cerumen, which varies in color and consistency from yellow and flaky to brown and sticky or even to dark and hard, may wholly or partly obscure your view.
- -In acute otitis externa, the canal is often swollen, narrowed, moist, pale, and tender. It may be reddened.
- -In chronic otitis externa, the skin of the canal is often thickened, red, and itchy

The Nose

Inspect the anterior and inferior surfaces of the nose.

Gentle pressure on the tip of the nose with our thumb usually widens the nostrils and, with the aid of a penlight or otoscope light, you can get a partial view of each nasal vestibule

Tenderness of the nasal tip or alae suggests local infection such as a furuncle.

Note any asymmetry or deformity of the nose.

Deviation of the lower septum is common and may be easily visible. Deviation seldom obstructs air flow.

Test for nasal obstruction if indicated by pressing on each ala nasi in turn and asking the patient to breathe in.


Inspect the inside of the nose with an otoscope and the largest ear speculum available

Tilt the patient's head back a bit and insert the speculum gently in to the vestibule of each nostril, avoiding contact with the sensitive nasal septum.

Hold the otoscope handle to one side to avoid the patient's chin and improve your mobility.

Pharynx

- Made by the anterior and posterior p



Thought processes -the logic, relevance, organization and coherence of patient's thought process as revealed in the patients speech during the interview

- Circumstantiality- "around the bush" talk, not to the point
- Derailment –loosing of association between different subjects of talk
- Flight of ideas-abrupt change from one topic to the other
- Neologism-invented words idiosyncratic meaning
- Incoherence-speech that is incomprehensible because of illogic
- Blocking-interruption of speech in mid-sentence.
- Perseveration-repetition of words or ideas
- Echolalia-repetition of words of others

Thought content-

- Compulsion-repetitive mental act a person is driven to do.
- Obsession-uncontrollable thoughts that a person considers unacceptable.
- Phobia-irrational fear accompanied by desire to avoid the stimulus.
- Anxiety- apprehensions.
- Feeling of unreality-a sense that things in the environment are strange
- Feeling of depersonalization-a sense of oneself being detached from one's body and mind
- Delusions-false belief that are not shared by other members of the person's culture.

EXAMPLES -Delusion of persecution, grandiose, delusion

Perception

- Illusion-misinterpretation of real external stimuli.
- Hallucination-subjective sensory perception in the absence of relevant external stimuli

Insight: -Denial of being sick is considered a lack of insight

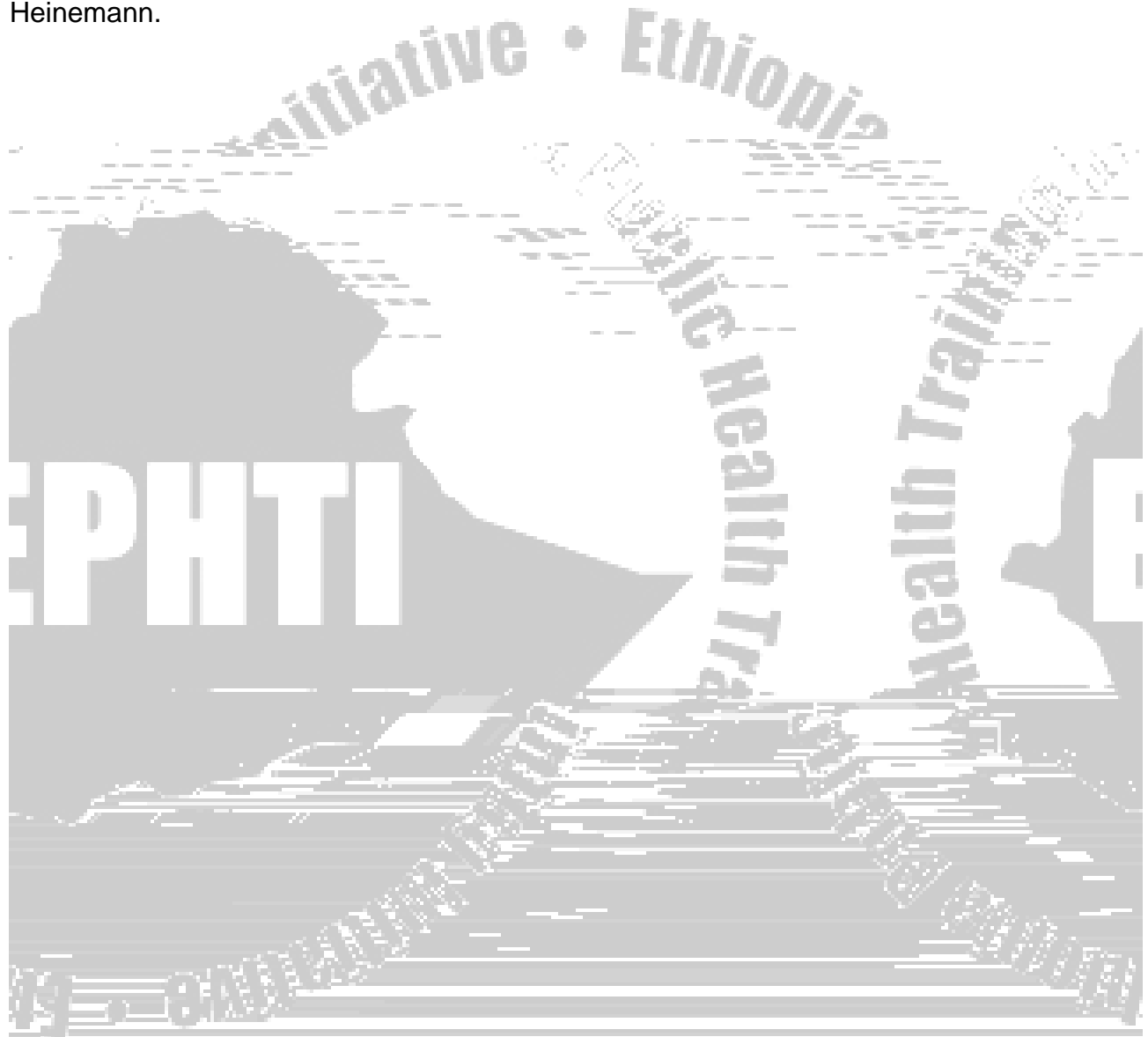
Judgment

-Questions like "how will you manage if you lose your job?" Will assess this capacity



REFERENCES

- 1-Barbara Bates, Guide to physical examination and history taking, 6th edition,1995, J.B. Lippincott company.
- 2-John Sanford Smith, Eye diseases in hot climate, 3rd edition,1997,Butterworth-Heinemann.



CHAPTER TEN

APPROCH TO EXAMINATION OF THE NERVOUS SYSTEM

Introduction:

The aim of neurological assessment is to asses the patients' illness in both functional and anatomical terms. A detailed examination is very important but tiresome for critically ill patients and over long examination may defect its own ends especially when sensation is tested. So examination should be planned in relation to the problems posed by the information acquired from the patient's history.

Objectives

At the end of this chapter the student should be able to:-

- 1- Describe important structures of nervous system
- 2-Describe important functions of nervous system
- 3-Do complete neuralgic examination
- 4- Interpret abnormal neurological findings
5. Localize the possible site of a lesion along the neuro-axis

NEUROANATOMY

The nervous system consists of the central nervous system and the peripheral nervous system. The central nervous system is made by the brain and the spinal cord. The peripheral nervous system consis

The BRAIN

The brain can be considered in two sections:

1. Supratentorial structures- these are parts of the brain above the tentorium

Cortex:-consists of the frontal, parietal, temporal and occipital lobes

Simplified functions of the cortical lobes:

1. The frontal lobe contains precentral cortex that controls motor function,
2. The parietal lobe contains postcentral cortex that controls sensory function
3. The occipital lobe contains visual cortex that controls vision,
4. The temporal lobe has some input in emotion and behaviour

Subcortex – contain the basal ganglia, thalamus, hypothalamus, internal capsule and other connections of the cortex.

2- Infratentorial structures- these are parts of the brain below the tentorium

- *Brainstem:-*consists of the midbrain, pones, and medulla
- *Cerebellum:-* controls coordination of motor activities, balance and gait

The SPINAL CORD


This structure contains the ascending and descending tracts from and to the brain. It is also the seat of anterior horn cell which marks the boundary between the central and peripheral nervous system. Affection of the anterior horn cells and below results in what we call a lower motor neuron lesion while those above give the upper motor neuron lesions.

There are ascending and descending pathways. Some of the major pathways are:

Corticospinal tracts: - which carries motor command from the motor cortex to the anterior horn cells. This controls voluntary motor function

Spinothalamic tracts: - which carries sensation of pain, temperature, pressure and touch from the periphery to the cortical sensory area

The dorsal (Posterior) column:



- One side of the brain is functionally dominant, usually the left hemisphere in almost all right handed individuals and in majority of left handed individuals
- In the areas of the central sulcus (border of frontal and parietal lobes) there are certain areas that relate to specific portions of the body (fig)
 - The face and head area is located inferiorly
 - Areas that relate to the upper extremities and trunk are located over the top of the brain, and those that control the lower extremity extend down into the parasagittal motor area.

Peripheral nervous system

- 1- Cranial nerves
- 2- Spinal nerves
- 3- Peripheral nerves
- 4- Neuromuscular junctions

NEUROLOGIC HISTORY

GENERAL CONSIDERATIONS

Common neurologic symptoms are

- Loss of consciousness
- Seizure (convulsion)
- Syncope
- Weakness or paralysis of part of the body
- Abnormal body movements like tremor
- Neurologic pain
- Altered or loss of sensation

Any neurologic symptom should be properly described by the patient. History may also be taken from the family or close friends who will fill gaps in the history due to memory loss, aphasia, loss of insight or loss of consciousness.

Temporal course of each symptom should be well explained

Onset: - *sudden or gradual:*

- Vascular lesions manifest within seconds to minutes as “*STROKE*”
- Effects of acute infections/inflammations progress over days
- Effects of chronic infections/inflammations progress over weeks to months
- Effects of Neoplasms progress over months to years.
- Degenerative diseases progress over many years

Course: - progressive, steady, improving

Parts of the body involved

Associated symptoms E.g. headache , vomiting , fever etc

Family history of neurologic disorder

Medical illnesses such as hypertension, diabetes, cirrhosis, renal failure, neoplasms, bleeding disorders etc... may be associated.

History of drug and alcohol abuse is very useful.


NEUROLOGIC EXAMINATION

Components:-

1. Mental status examination
2. Cranial nerves examination
3. Motor examination including deep tendon reflexes
4. Superficial reflexes
5. Primitive reflexes
6. Motor Coordination
7. Examination of posture, station and gait.
8. Examination for signs of meningeal irritation

MENTAL STATUS Examination:-

A thorough evaluation of the patient's mental status reveals information about the patient as a person, the presence of mental illness, organic brain disease, and finally, about the patient's reaction to illness and his ability to deal with it.



4. Thought and perception

- ◆ Observe the patient for logic and coherence.
- ◆ Any unusual aspects of thought, illusions or delusions, perseveration and insight.

5. Cognitive function

- ◆ Orientation to time, place, and person.
- ◆ Assess the three aspects to memory, which usually becomes obvious during the interview.

1 -*Immediate recall* by saying a series of numbers and having the patient repeat them.

2-*Recent memory*

- Small object or a moving finger is slowly moved from the periphery to the center until noted by the patient
- This is compared with the examiners field of vision and done in all quadrants.

b) Using perimeter

2.2 Visual acuity: - may be checked by

- Snellen's chart (see special exam in the next chapter)
- Use finger counting and reading.

2.3 Checking for colour vision-

- Using Ishihara's test
- Asking the individual to identify different colours in the plate (extra 13.0006.01557) 9.28 F2.72E

Then test the movement of the eye balls in all directions

Examine the pupils for: -

- Size, Symmetry,
- Pupillary light reflex
 - In dimly lighted room ask patient to look into the distance.
 - Shine a bright light obliquely into in to each pupil in turn.
 - Look for both direct (same eye) and consensual (other eye) pupillary light reactions
 - Record pupil size in millimetres and any asymmetry or irregularity
- Accommodation
 - Hold a finger at 10 cm from the patient nose.
 - Ask patient to look alternatively at your finger and into the distance.
 - Observe the pupillary response in each eye and converging movement of the eyeballs.

4. The fifth cranial (Trigeminal) nerve:- It has motor and sensory components

- *Motor branch* supplies the masseter, temporalis and lateral pterigoid muscles
- *Sensory branch* supplies the skin of the face and anterior part of the scalp. It also supplies the mucous membrane of the mouth and cornea

It has three sub- branches

- Ophthalmic
- Maxillary and
- Mandibular divisions

Examination of the fifth cranial nerve includes:

- *Motor examination of jaw movement* -Patient is asked to extend the jaw, move it from side to side, and bite strongly. Palpate the masseter and temporalis muscles as the patient clenches his teeth.

- *Sensory examination of the three divisions of the trigeminal nerve*-the examiner tests light-touch sensibility with a cotton and pain by pricking with a pin the patient's forehead, the area of the mandible and the maxilla.
- *Corneal reflex*- The patient is asked to look upward while the examiner uses the wisp of cotton carefully and to briefly stroke the cornea from the side and from below. The normal response is blinking.

5. The seventh (facial) nerve: - has two major functions

- Motor branch supplies all muscles of facial expression
- Sensory branch supplies taste buds of anterior 2/3 of the tongue

Evaluation of the motor function

Inspection for flattening of the nasolabial fold, facial droop or asymmetry

Then ask the patient to

- ◆ Frown, raise eye brows
- ◆ Close his eye tightly against pressure,
- ◆ Smile or show upper teeth,
- ◆ Blow cheek
- ◆ Whistle.

Supranuclear facial palsy:- is due to lesions of facial nerve above the nucleus (upper motor). The muscles for frowning and closing of the lids are spared because these muscles get fibres from both hemispheres. But the other facial muscles are affected..

Infranuclear facial palsy:- is due to lesions to the facial nerve nucleus or after coming out of nucleus. In this case all the muscles of facial expression are affected .

The sensory portion of the seventh nerve:- is tested by applying crystals of salt and sugar from two moistened cotton applicators on different aspects of the tongue.

6. The eighth (vestibule-cochlear) nerve: - it mediates the sense of hearing and also important for rotational perception and keeping balance.

Testing Cochlear portion is done by assessing the ability to hear using:-

- Whispered and spoken voice, tickling of a watch etc.
- **Weber's test** tests for lateralization: Place the vibrating tuning fork on top of the patient's head and, ask patient in which ear he hears it best. In conduction problems sound lateralizes to the abnormal ear and in neural deafness to the normal ear.
- **Rinne's test** to compare air conduction to bone conduction: Place the vibrating tuning fork on the mastoid bone with ear closed first, then Place the "U" of vibrating tuning fork at the ear as soon as patient reports no vibration from mastoid bone. In conductive deafness bone conduction is longer than air conduction. In sensory neural hearing loss, sound is heard longer through the air.

Vestibular portion of the eighth nerve is evaluated during testing of the extra ocular movements, the examiner observes for nystagmus.

7. The ninth cranial (glosso pharyngeal) nerve mediates


- Taste sensation from the posterior 1/3 of the tongue
- Motor supplies to muscles of the pharynx

Examination includes

- Checking for taste over the posterior third of the tongue.
- A portion of the ninth nerve and a portion of the tenth nerve are tested by the gag reflex, elicited by stimulating the posterior tongue with a tongue depressor.

Coughing after swallowing liquid, suggest the possibility of vagal involvement

9. The eleventh cranial (accessory) nerve: - Originates from t



Muscle tone may be

Normotonic: - found in normal individuals

Hypotonic: - found in patients with lower motor lesion, spinal shock etc.

Hypertonic (spasticity / rigidity):-this may be of different type

e.g. Clasp knife rigidity which may be found in upper motor lesions

Cog- Wheel rigidity which is found in Parkinsonism.

Muscle power

Screening tests for muscle strength

In the Upper limbs

- *Hand Grip:* - is assessed by testing and comparing bilateral hand grips. The patient is asked to grip objects or while the examiner tries to remove the object from his hand.
- *Pronator drift:* - is a sensitive test for mild weakness in the upper limbs. Tell the patient to extend his hands, palms up, straight at shoulder level and to close his eyes. If weakness is present, there is drift downward on the affected side.

In the Lower limbs

The patient is asked to jump or hop.

Then proceed to examine power of each muscle group at every joint by pulling or pushing in the direction opposite to its action. Antigravity muscles are best evaluated by walking on toes (plantar flexors), and rising from a chair without using the hands (hip extensors and knee extensors)

Muscle power grading scale

0= no movement

1= flickering of fingers

2= horizontal motion on bed

3= movement against gravity (vertical motion)

4= movement against gravity and power

5= full power

DEEP TENDER REFLEXES

The Deep tendon reflexes that are examined include

Upper limbs:-

Biceps (C_5 C_6),
Triceps (C_7 , C_8) and
Brachioradialis (C_5 C_6)

Lower limbs

Patellar / Knee jerk (L_3 , L_4) and
Achilles tendon / Ankle (S_1 , S_2)

Biceps reflex

Flex arm at the elbow
Place finger firmly on the biceps tendon
Strike your finger with the reflex hammer.

Triceps reflex

Support arm and let forearm hang freely
If patient is sitting strike the triceps tendon above the elbow with the broadside of the hammer
If patient is lying flex the arm at the elbow and hold close to the chest.

Knee jerk reflex

Have the patient lie down with the knee flexed.
Strike the patella tendon just below the patella.
Note contraction of the quadriceps and extension of the knee

Ankle reflex

Dorsiflexion of the foot at the ankle
Strike the Achilles tendon
Watch and feel for plantar flexion at the ankle.

Reflexes grading scale

- 0= Absent
- 1= Present but diminished
- 2= Normal
- 3= Brisk (exaggerated)
- 4= Exaggerated reflexes with clonus

SUPERFICIAL REFLEXES

In the presence of upper motor-neuron lesions, the superficial reflexes are attenuated.

The superficial abdominal reflex: - is tested by lightly stroking the skin of the abdomen from above downward and laterally to medially. Generally reflex is more easily elicited in the upper abdomen.

The cremasteric reflex: - is tested by pinching or stroking the skin of the medial aspect of the thigh. Contraction of the cremasteric muscle occurs, resulting in elevation of the testis on the same side.

Plantar reflex: - is tested by scratching the sole of the patient's foot from the heel toward the toes and observes the movement of the toes. The response could be

- *Normal* :- downward (plantar) flexion of all toes
- *Equivocal* :- no response
- *Up going plantar (Babinsky's Sign)*:- An upward movement of the great toe with fanning or spreading of the other toes. This is a pathological reflex which is often found in Upper motor neuron lesions.

PRIMITIVE REFLEXES

In diseases of bilateral cortical involvement and often the frontal lobe several reflexes present during early infancy but which are not present in adulthood reappear. Some of these are:

1. *Sucking reflex* - when the centre of the lip is touched with a tongue blade there is a sucking movement of lips.

2. *Rooting reflex*- when the corner of the lips are touched with the tongue blade the lips move towards the blade.
3. *Grasp reflex*- touching of the palm between the index finger and the thumb will stimulate forced grasp.
4. *Palmomental reflex*- scratching of the palm diagonally results in the contraction of ipsilateral mentalis muscle.
5. The *snout reflex* is elicited by tapping the patient's lips with the reflex hammer. If the reaction is positive, a pursing movement of the lips occurs after each tap.



Pain and temperature sensation tests (spinothalamic)

- Pain sensation is tested with a sterilized pin.
- Temperature tested by using hot and cold test tubes

Position and vibration sensation tests (posterior column)

- Position sense or proprioception is tested by asking the patient to close eyes, and the examiner moves the patient's finger or toe up or down while the patient interprets the action
- Vibratory test needs a tuning fork which is placed over bony prominences such as the wrist, elbow, medial malleoli, patellae, anterior superior iliac spine, spinous processes and clavicle.

CENTRAL (CORTICAL) SENSATION

The cortical sensation is also referred to as *central or discriminative* sensation. In lesions of the cortex the peripheral sensations like pain, temperature, pressure, touch, and vibration are not affected.

- 1- Sterognosis-identify objects by touching while the eyes are closed
- 2- Graphstesia-identify numbers or letters written on the skin surface with eyes closed
- 3- Two point differentiation-identify two closely approximated stimuli as separate.
- 4- Point localization with the eyes closed

EVALUATION OF COORDINATION

Coordination is smooth, accurate performance of motor activity.

Testing coordination in the upper extremities include:-

- o Finger - to - Finger test
- o Finger - to Nose test
- o Rapid altern98 73h n(d altern98 7)JmeVpat7 Nom([]-621(r1tify two cl)JJs.125 -1.73 T

o

EXAMINATION OF GAIT, POSTURE AND STANCE

- ◆ Ability to stand with heels and feet together and eyes closed (Romberg).
- ◆ The patient is then asked to walk normally and with tandem gait (placing foot directly in front of the other repetitively), first with the eyes open and with them closed.
- ◆ The broadness, steadiness, and symmetry of the gait are observed.

Shuffling /stooping gait-Parkinsonism

Broad based gait- ataxia

Scissoring gait-spasticity

Slapping gait -posterior column affection.

EXAMINATION FOR SIGNS OF MENINGEAL IRRITATION

1. **Neck stiffness**- involuntary rigidity of the neck due to pain arising from meningeal irritation.
2. **Kerning's sign**- the thigh is first flexed and then the leg is extended at the knee while patient is lying on his back. This will stretch the nerve root and pain will be elicited at the inflamed meninges.
3. **Brudzinsky's sign**-when trying to flex the neck of patient with meningeal irritation the knees will automatically flex to prevent stretching of the meninges.

TIPS TO NEUROLOGIC LOCALIZATION

SPECIFIC CONSIDERATIONS IN THE HISTORY

When approaching a patient with neurologic disease begin distally and ask questions about each part of the nervous system beginning with the neuromuscular junction, then the peripheral nerve, spinal roots, spinal cord, cerebellum, brainstem, sub cortex, and the cortex. Here is a list of question that one could ask. A "positive "or a "'YES' answer will support possibility of lesion in that particular anatomic location.

1 -Neuromuscular junction

- “Fatigability”. - Does weakness worsens with use of muscle and recovers with rest?
- “Small muscle weakness”-ptosis, double vision, chewing difficulty, slurred speech?

2-The peripheral nerve

- “Distal weakness”-frequent dropping of things or tripping?
- “Asymmetry” –one side of body? (rarely symmetric)
- “Sensory changes”-numbness, tingling parasthesia?
- “Atrophy”-wasting of affected muscles?
- “Fasciculation”-twitching of muscle?

3-Spinal roots

- All things like peripheral nerve but associated with radicular severe pain.

4-Spinal cord

- “Sensory level”-is there a belt or band of around waist or thorax?
- “Symmetric weakness”?
- Bowel and bladder control loss-is there retention or incontinence?

5-Cerebellum

- “Arm coordination”-difficulty of putting a key into the lock?
- “Leg coordination”-drunken walk?

6-Brainstem

- Cranial nerve involvement?
- Hemiparesis and hemisensory loss?
- “Crossed paralysis” -Are the above deficit crossed?

7-Subcortex

- Numbness of one side of the body? Loss of pain sensation?
- Equal affection of face, arm and leg with weakness and numbness?
- Movement disorders (tremor) athetosis, hemiballismus?

8-Cortex

Aphasia?

Seizure?


Intact sensation to pain?

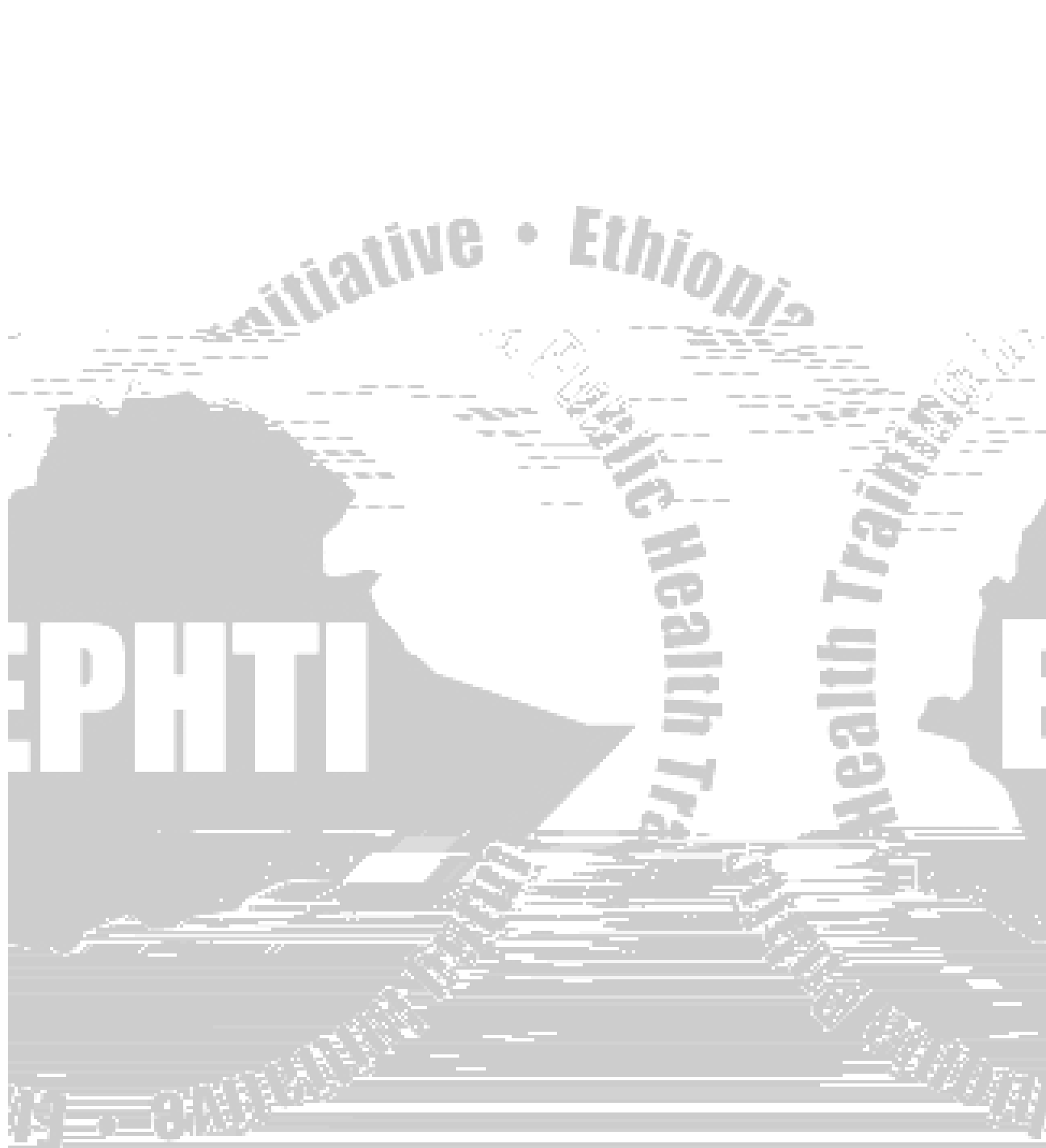
Weakness of arm and body on same side?

Weakness of the arm and leg is not uniform

Cortical sensory deficit?

Lesions of the Motor System






Public Health Training
Initiative • Ethiopia
EPHTI
Public Health Training
Public Health Training
2019 • 8th Edition

Review Questions

1. Describe the difference between upper and lower motor lesions?
2. Mention cardinal features of cortical lesions?
3. What are the features of brain stem lesion?



REFERENCES

1. Barbara Bates-A Guide to Physical Examination and History Taking, 6th Edition, 1995,
2. Harrison's Principals of Internal Medicine, 15th Edition, 2001.
3. Antony J.Zollo-Medical Secrets, 1st Edition 1991, Jaypee Brothers.

